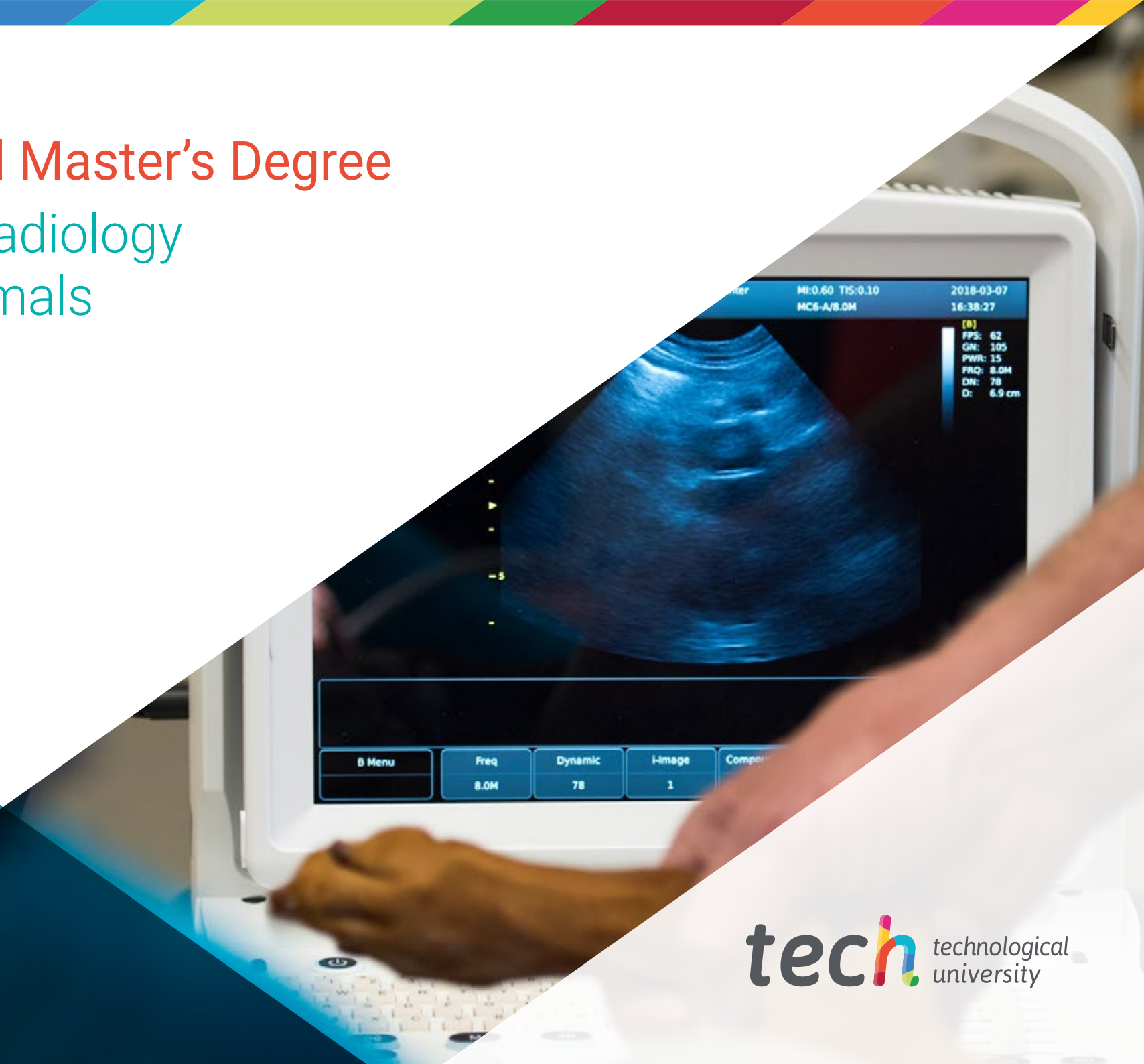

Professional Master's Degree

Veterinary Radiology in Small Animals





Professional Master's Degree Veterinary Radiology in Small Animals

- » Modality: online
- » Duration: 12 months
- » Certificate: TECH Technological University
- » Dedication: 16h/week
- » Schedule: at your own pace
- » Exams: online

Website: www.techtute.com/in/veterinary-medicine/professional-master-degree/master-veterinary-radiology-small-animals

Index

01

Introduction

p. 4

02

Objectives

p. 8

03

Skills

p. 16

04

Course Management

p. 20

05

Structure and Content

p. 26

06

Methodology

p. 40

07

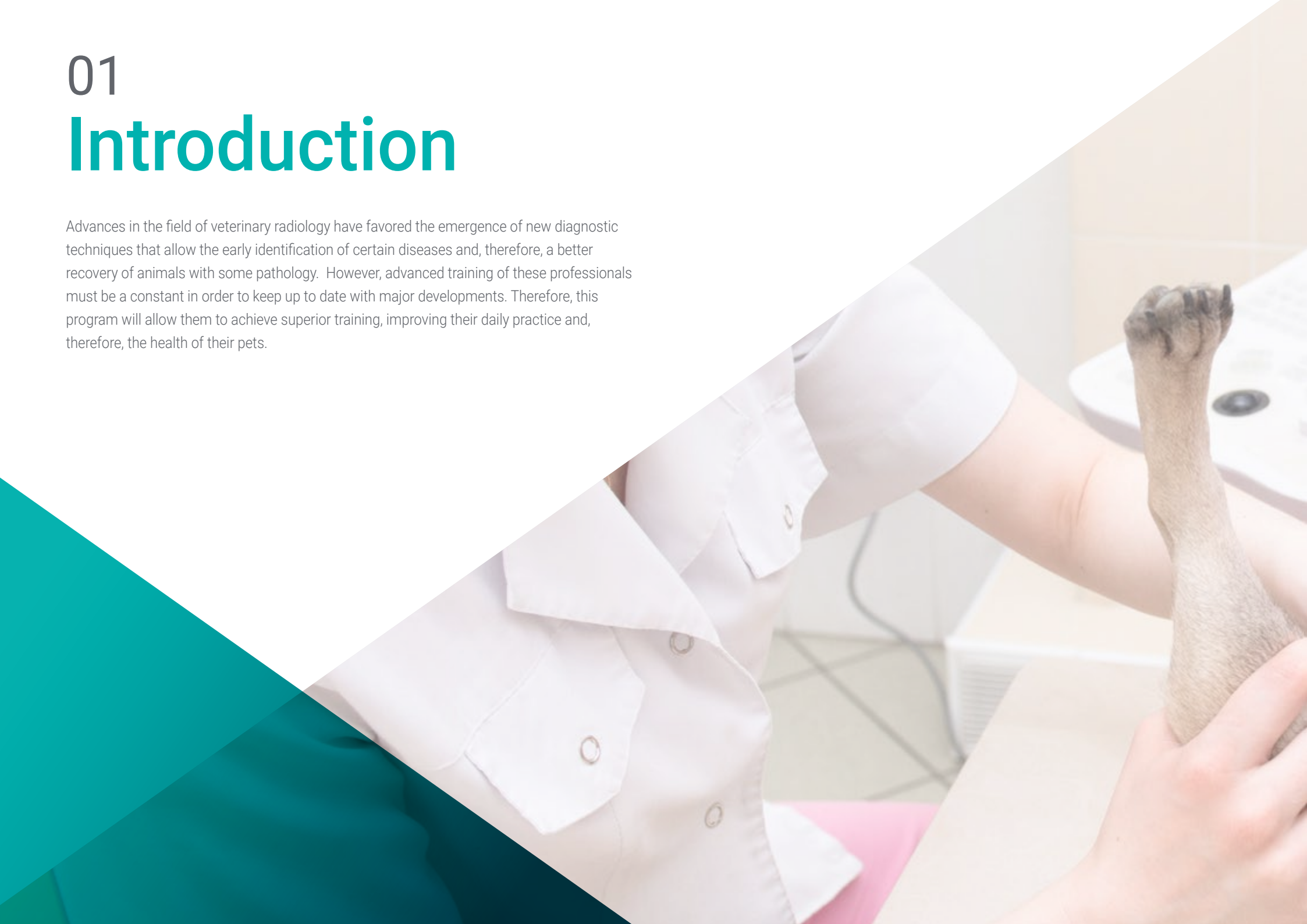Certificate

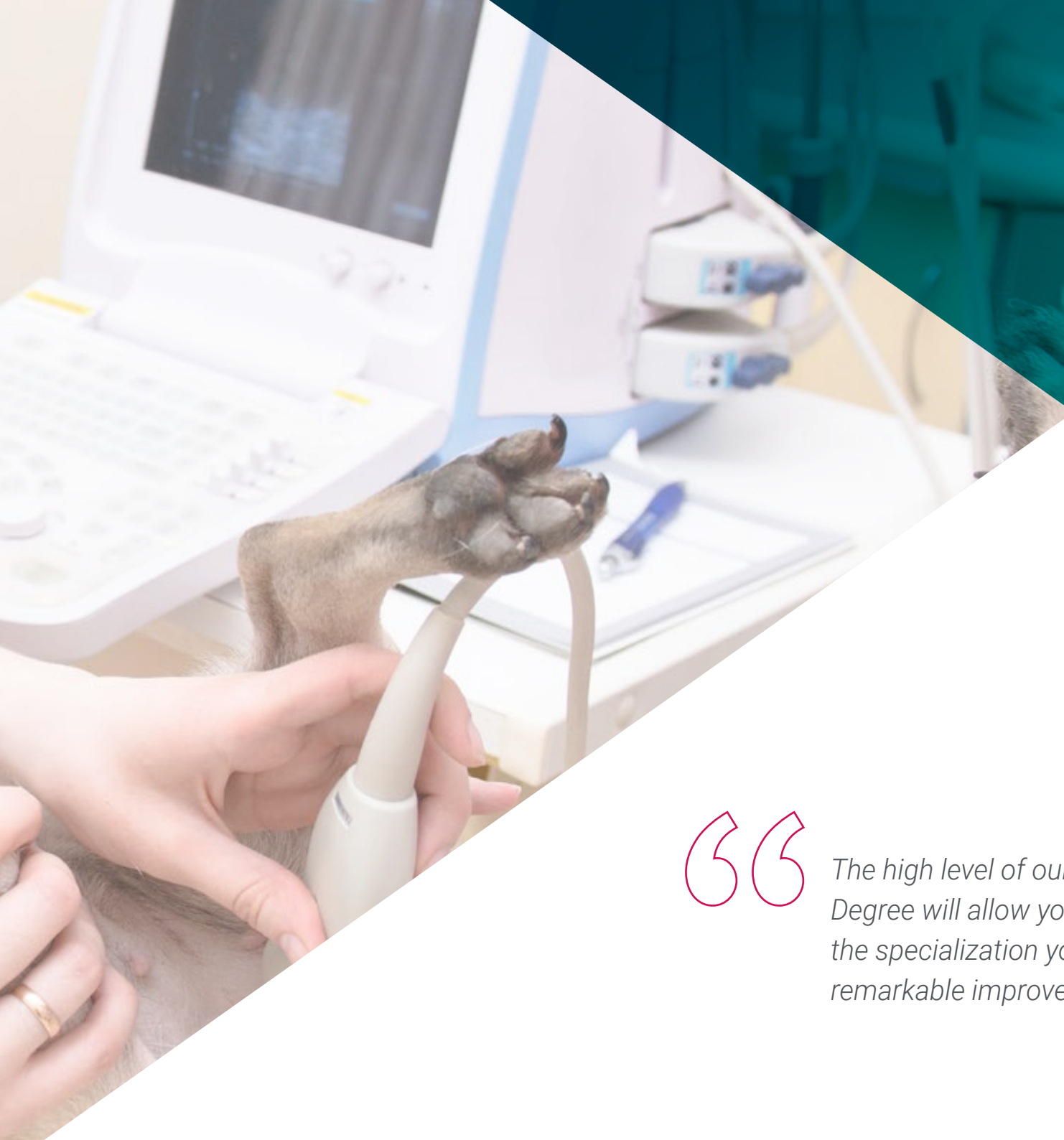p. 48

01

Introduction

Advances in the field of veterinary radiology have favored the emergence of new diagnostic techniques that allow the early identification of certain diseases and, therefore, a better recovery of animals with some pathology. However, advanced training of these professionals must be a constant in order to keep up to date with major developments. Therefore, this program will allow them to achieve superior training, improving their daily practice and, therefore, the health of their pets.





“

The high level of our Professional Master's Degree will allow you to acquire in a short time the specialization you are looking for, achieving a remarkable improvement in your daily practice"

The study of veterinary radiology online is a reality nowadays, since the existence of better and better technological tools allows the possibility of learning this specialty through a screen. For this reason, TECH takes advantage of the ease of the network to provide students with the most complete educational experience of the moment, through an innovative methodology that allows for a contextual study of the cases presented. In addition, studies have shown that the veterinarian who has become familiar with radiological images and associates them with the different pathologies will have a much better diagnostic capacity in the future, therefore, the clarity offered by the new technologies allows the learning process to be complete.

For the realization of this Professional Master's Degree, the teaching team of our university has made a careful selection of the different radiological diagnostic procedures, together with other diagnostic alternatives for veterinary professionals. In this way, clear clinical guidance is provided by the use of radiology to resolve the diagnosis of small animal diseases without forgetting the wide variety of other diagnostic options that are of great use in veterinary practices.

In short, it is a program based on scientific evidence and daily practice, with all the nuances that each professional can contribute, so that the student can keep it in mind and compare it with the bibliography and enriched by the critical evaluation that every professional must have in mind.

Thus, throughout this training, the students will go through all the current approaches to the different challenges of their profession. A high-level step that will become a process of improvement, not only on a professional level, but also on a personal level. In addition, TECH assumes a social commitment: to help the updating of highly qualified professionals and to develop their personal, social and work skills throughout the duration of the course. And, to do so, it will not only take you through the theoretical knowledge offered, but will show you another way of studying and learning, more organic, simpler and more efficient. It works to maintain motivation and to create a passion for learning; it encourages thinking and the development of critical thinking.

This **Professional Master's Degree in Veterinary Radiology in Small Animals** contains the most complete and up-to-date scientific program on the market. The most important features include:

- ♦ The development of case studies presented by experts in Veterinary Radiology
- ♦ The graphic, schematic, and eminently practical contents with which they are created, provide scientific and practical information on the disciplines that are essential for professional practice.
- ♦ Latest developments in Veterinary Radiology
- ♦ Practical exercises where the self-assessment process can be carried out to improve learning
- ♦ Special emphasis on innovative methodologies in Veterinary Radiology
- ♦ Theoretical lessons, questions to the expert, debate forums on controversial topics, and individual reflection work
- ♦ Content that is accessible from any fixed or portable device with an Internet connection



The studies in Veterinary Radiology will allow you to use the main diagnostic imaging techniques with total confidence"

“

This training, in e-learning format, will give you the possibility to expand your knowledge with a multitude of virtual tools, making your learning faster and more effective”

Its teaching staff includes professionals belonging to the veterinary field, who contribute their work experience to this training, as well as renowned specialists from reference societies and prestigious universities.

The multimedia content, developed with the latest educational technology, will provide the professional with situated and contextual learning, i.e., a simulated environment that will provide immersive training programmed to train in real situations.

This program is designed around Problem Based Learning, whereby the specialist must try to solve the different professional practice situations that arise during the academic year. For this purpose, the professional will be assisted by an innovative system of interactive videos made by renowned and experienced experts in Veterinary Radiology.

Our innovative methodology has a great success among our students, due to the benefits it provides for a contextual study, which allows them to learn better.

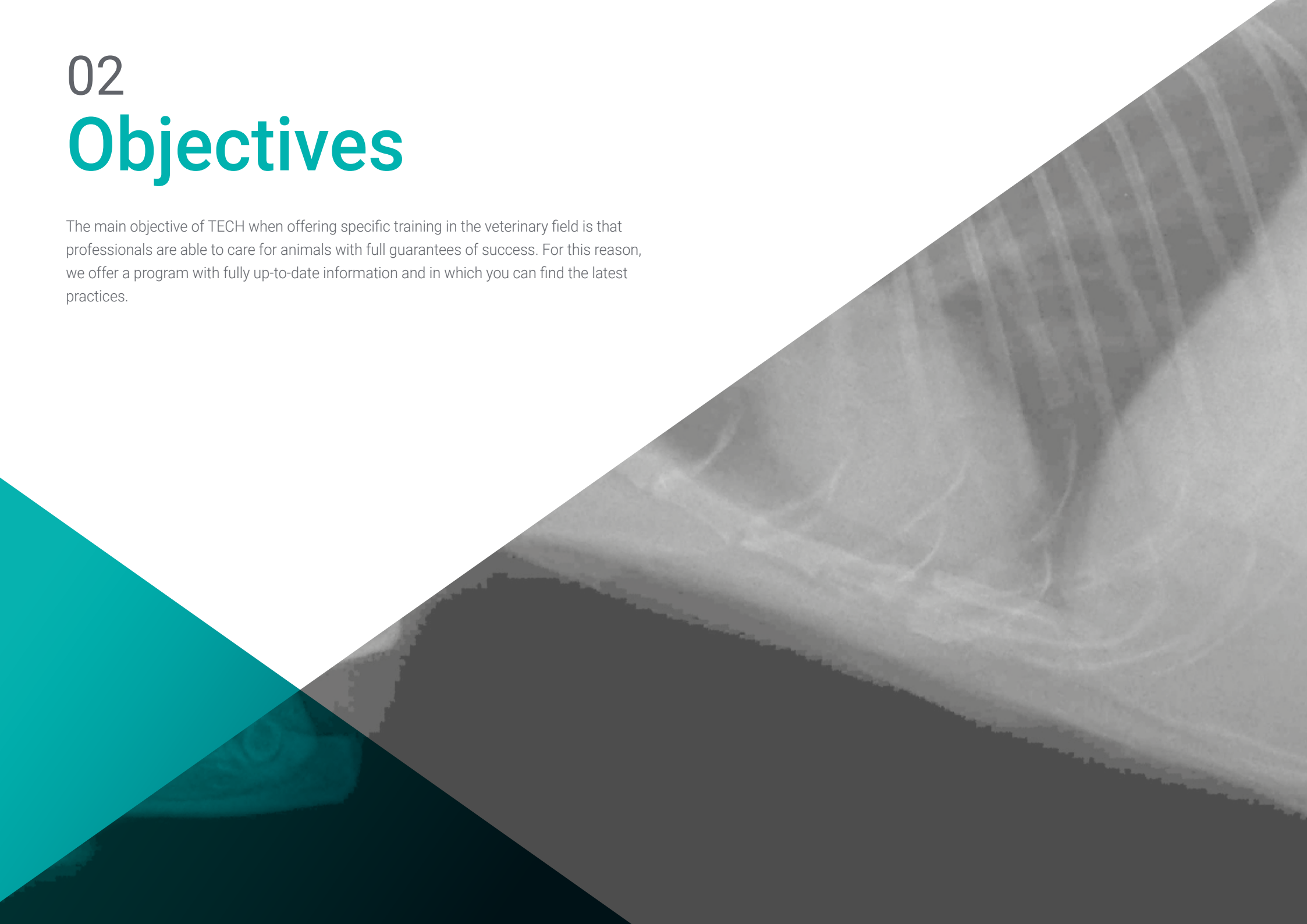
Learn efficiently, with a real qualification objective, with this Professional Master's Degree, unique for its quality and price, in the online teaching market.



02

Objectives

The main objective of TECH when offering specific training in the veterinary field is that professionals are able to care for animals with full guarantees of success. For this reason, we offer a program with fully up-to-date information and in which you can find the latest practices.



“

Ongoing training for veterinary professionals will enable them to keep up to date with the latest practices that they can apply in their offices"



General Objectives

- ♦ Analyze how the clinical radiological image is formed
- ♦ Examine the drawbacks and distortions in the image obtained
- ♦ Establish the relationship between the radiological technique and the object to be X-rayed
- ♦ Determine the concept of homogeneous reproduction of the technology
- ♦ Examine the physics of ionizing radiation
- ♦ Establish the different types of protection measures
- ♦ Address current legislation on the use of ionizing radiation
- ♦ Identify and describe the radiological signs that are consistently observed
- ♦ Establish differential diagnoses based on what is observed
- ♦ Identify the most likely diagnosis and reason it out
- ♦ Examination of other imaging tests could be performed to refine the diagnosis
- ♦ Prepare a radiological report and make a diagnostic judgement
- ♦ Establish the most relevant anatomical details for a correct evaluation of the thoracic structures
- ♦ Define the criteria for a correct radiographic technique of the thorax
- ♦ Examine the physiological and pathological image of the different structures that can be found in the thorax
- ♦ Examine the most frequent pathologies that we can diagnose through the use of Radiology
- ♦ Determine the diagnostic method of digestive diseases and the tests of choice for each moment
- ♦ Analyze how to optimize the diagnosis and the limitations of each technique
- ♦ Establish the most relevant anatomical details for a correct evaluation of the abdominal structures
- ♦ Define the normal and pathological anatomical image of each organ
- ♦ Specify the various differential diagnoses according to the radiological image observed
- ♦ Identify the normal radiographic anatomy of the central nervous system as a basis for good interpretation
- ♦ Analyze the radiological signs of the main diseases affecting the nervous system
- ♦ Develop a systematic approach to the evaluation of radiologic images of the nervous system and obtain the maximum diagnostic information
- ♦ Present the most frequent diagnostic errors in the interpretation of radiological images during the study of the central nervous system
- ♦ Determine the normal anatomical picture of the structures forming the neurological system, mainly the spine and skull
- ♦ Define the main pathological alterations that can be observed in radiographs
- ♦ Examine the myelography technique
- ♦ Examine the specific anatomy in order to extrapolate the different orthopedic pathologies at the radiological level
- ♦ Analyze the functioning of the growth plate in order to have an adequate perception of the radiological evolution of the bone
- ♦ Develop the radiological evolution of the bone after a fracture
- ♦ Radiological visualization of bone healing
- ♦ Generate specialized knowledge to prevent complications in our clinical/surgical practice
- ♦ Determine the importance of arthritis/arthrosis in our daily clinical practice
- ♦ Be able to make a clinical prognosis through an orthopedic radiological study



- ◆ Determine the limitations of certain radiological studies to diagnose certain orthopedic pathologies and the different types of surgical techniques in traumatology and orthopedics
- ◆ Extrapolate the knowledge of these techniques in vivo to visualize the evolution
- ◆ Determine radiographic projections and positioning to obtain images with greater diagnostic value
- ◆ Examine the radiographic anatomy of the forelimb and hind limb, looking at the differences between species and breeds
- ◆ Identify the different types of fractures, treatment possibilities and assess their evolution and possible complications with a radiological study
- ◆ Differentiate a physiological bone tissue from a pathological one, and we will know what steps to follow to reach a diagnosis Identify pathological fractures
- ◆ Determine the limitations of radiological studies for the diagnosis of certain orthopedic pathologies
- ◆ Examine other diagnostic methods: Diagnostic Imaging
- ◆ Develop specialized knowledge for the correct identification of ultrasound, CT and MRI (Magnetic Resonance Imaging) images
- ◆ Identify when our patient needs advanced imaging studies
- ◆ Determine in which specific cases imaging techniques can help us in clinical diagnosis
- ◆ Examine the peculiarities of the positioning of exotic animals
- ◆ Perform radiography in an appropriate manner, according to the species and physiological anatomy
- ◆ Distinguish between pathologic findings and physiologic findings



Specific Objectives

Module 1. Ionizing Radiation for Diagnostic Purposes

- ♦ Analyze the Bremsstrahlung effect
- ♦ Interpret the cause of radiological defects and distortions
- ♦ Reproduce the systematic interpretation of the radiological image
- ♦ Differentiate the different types of radiological image processing
- ♦ Examine the concept of radiological distortion, the concept of pareidolia, and the concept of limiting factor

Module 2. Radioprotection

- ♦ Analyze the members of a radiology team
- ♦ Establish the different types of receivers of the generated radiation
- ♦ Present the existing types of dosimeters
- ♦ Assume the annual quality controls of the UTPR
- ♦ Examine the various consequences of correct and incorrect use of the installation and legal its legal repercussions
- ♦ Present the legislation in force for the use of radiodiagnostic equipment

Module 3. Radiodiagnosis of the Cardiovascular System

- ♦ Identify enlargements of the different cardiac chambers
- ♦ Examine the anatomy of the large vessels
- ♦ Determine the limits of radiology to assess cardiac function
- ♦ Analyze normal morphological variations as a function of the cardiac cycle
- ♦ List the projections necessary to visualize the cardiac silhouette optimally
- ♦ Address the assessment of arteries and veins of the pulmonary lobes
- ♦ Identify radiographic signs of cardiac alterations

Module 4. Radiodiagnostics of the Respiratory System and Other Intrathoracic Structures

- ♦ Determine the main limiting factors in the interpretation of thoracic radiographs
- ♦ Determine which projection(s) are the most appropriate according to the reason for the radiographic study
- ♦ Examine the normal and pathologic radiological image of the rib cage, the mediastinum, and its structures and of the structures present inside the thoracic cage
- ♦ Analyze the different pulmonary patterns and their main differential diagnoses
- ♦ Establish the radiological picture of the main congenital diseases affecting the thorax

Module 5. Radiodiagnosis of the Digestive System

- ♦ Radiological assessment of the most frequent pathologies of the esophagus, stomach, small intestine and colon
- ♦ Improve the radiological technique by means of the most frequent positionings
- ♦ Determine the limitations of radiology and the uses of complementary techniques to make accurate diagnosis

Module 6. Radiodiagnosis of the Rest of Abdominal Structures

- ♦ Define the normal and pathological radiological image of the liver, spleen and pancreas
- ♦ Analyze the physiological and pathological radiological image of the excretory system and genital apparatus
- ♦ Examine the radiological image of the retroperitoneal space and peritoneum
- ♦ Determine the oncological image of each of these structures

Module 7. Radiological Diagnosis in Neurology

- ♦ Propose the use of plain radiography and contrast radiological studies for the approach to the diagnosis of some inflammatory diseases of the central nervous system: infectious and non-infectious
- ♦ Establish radiological signs compatible with herniated discs and other degenerative diseases
- ♦ Justify the use of radiography as a diagnostic tool for the initial evaluation of the patient with spinal cord trauma
- ♦ Define the radiological patterns of myelography for the diagnosis of intradural (meningioma) and extradural (ependymoma and astrocytoma) tumors

- ♦ Identify radiologic signs secondary to metabolic and nutritional pathologies that cause encephalopathy
- ♦ Present the congenital anomalies of the central nervous system and surrounding bony structures that can be identified by radiographic study
- ♦ Examine the normal anatomical image of each spinal segment and the skull
- ♦ Improve the radiographic technique and positioning of the animal for the assessment of the neurological system
- ♦ Identify the congenital pathologies that can be observed in the spine
- ♦ Determine the different limitations encountered when assessing the skull
- ♦ Examine the cranial pathologies that can be observed by radiography
- ♦ Define the normal anatomical image of each spinal segment and the skull


Module 8. Orthopedic Radiological Diagnosis I

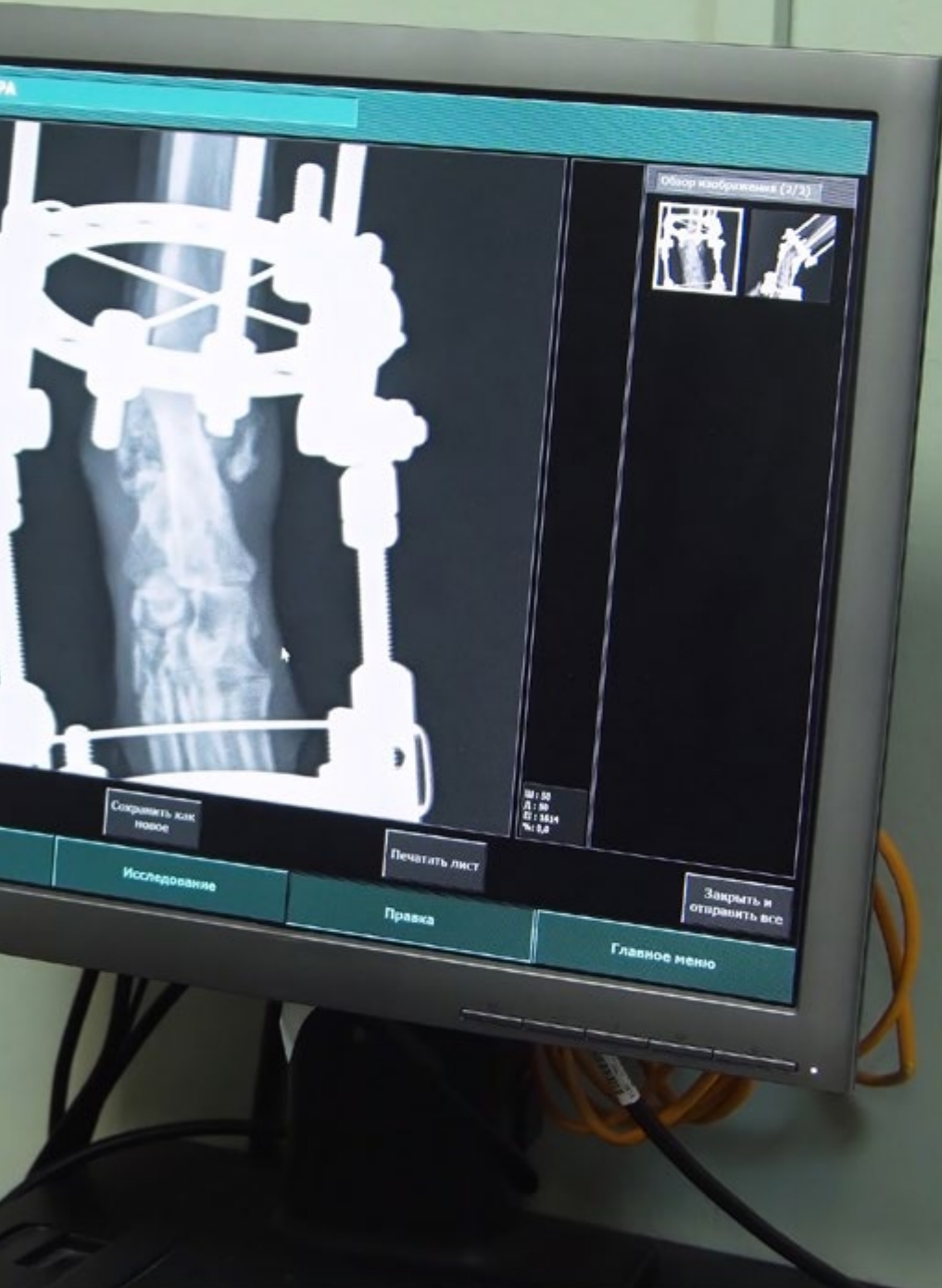- ♦ Determine the organization of the growth plate to understand its impact on radiological imaging
- ♦ Examine the blood supply to the bone in order to extrapolate radiologically to the bone and its cicatricial evolution
- ♦ Visualize bone and fibrocartilaginous components radiologically
- ♦ Determine the stages of fracture repair and identify them radiographically in order to be able to apply this knowledge during a postoperative recovery period
- ♦ Anticipate possible complications in the bone healing phase by means of radiological monitoring
- ♦ Correctly visualize the different types of complications and differentiate between them

- ♦ Examine radiographically a case understanding its clinical significance, as well as the evolution of the arthritis/arthritis
- ♦ Differentiate the various orthopedic diseases through radiographic study
- ♦ Correctly diagnose and classify orthopedic diseases associated with the knee, hip and elbow
- ♦ Recognize radiographically the different types of surgical procedures of choice to treat these diseases

Module 9. Orthopedic Radiological Diagnosis II

- ♦ Determine how to differentiate stable/unstable hip fractures and consider medical or surgical treatment
- ♦ Recognize femur fractures, and their importance in early diagnosis to avoid serious complications
- ♦ Examine the structures of the skull, jaw and teeth, emphasizing the importance of correct projections and showing the limitations of radiology in the structures of the the skull
- ♦ Identify tibial fractures
- ♦ Analyze the importance of radiographs in the forelimb by examining its anatomy and analyzing the most typical fractures in this area
- ♦ Examine radiologically the different pathologies of the distal extremity
- ♦ Improve radiological positioning for the assessment of dislocations
- ♦ Differentiate between the different types of joint dislocations
- ♦ Correctly diagnose and classify the different fractures at the level of the growth nucleus and involving the adjacent epiphysis and metaphysis
- ♦ Identify the different muscle, tendon and ligament pathologies by radiological imaging and understand their limitations





Module 10. Other Diagnostic Imaging Methods. Diagnosis in Other Species. Exotic Animals

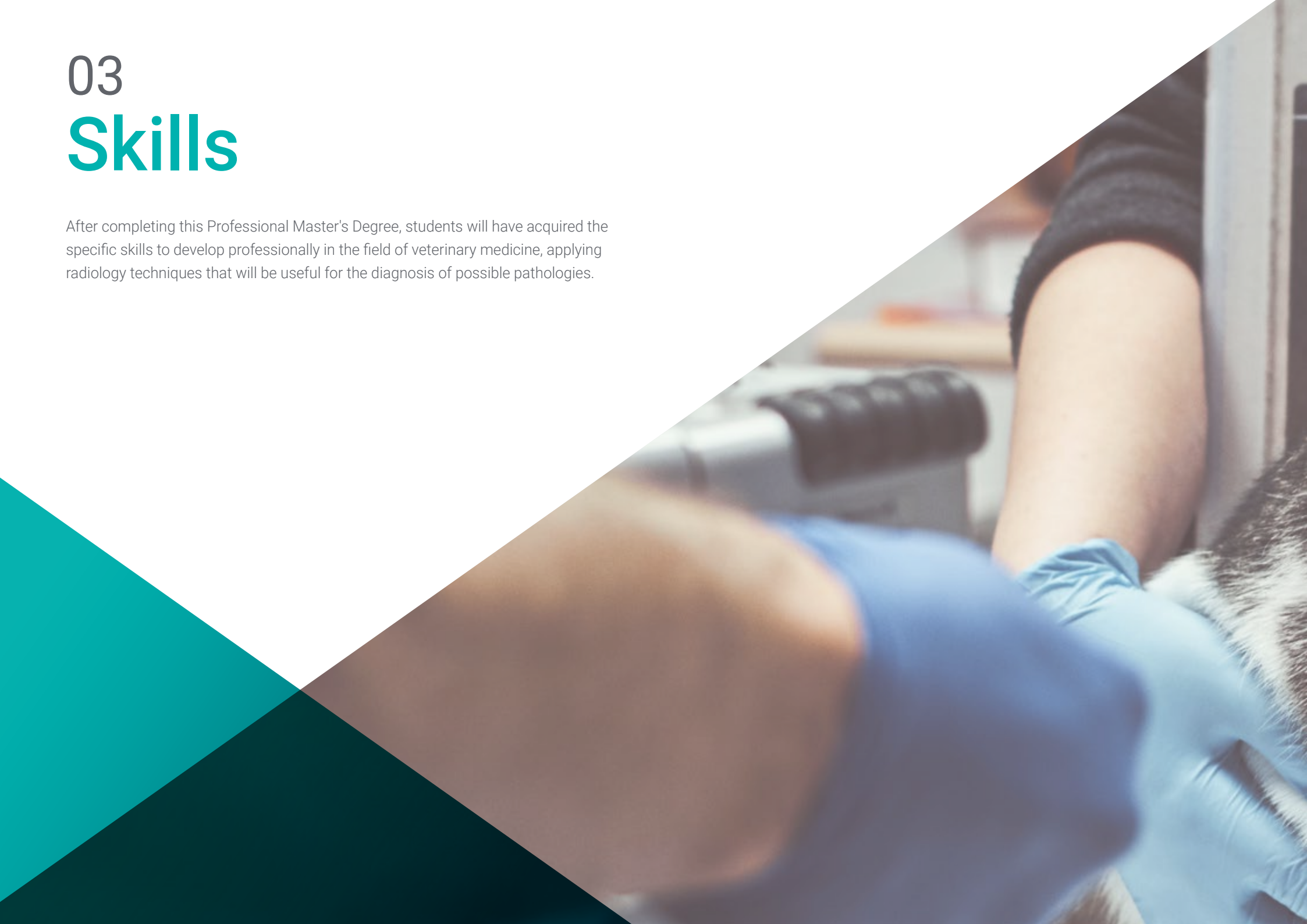- ◆ Develop specialized knowledge to perform ultrasound scans quickly, identifying the main pathologies
- ◆ Examine the ECOFAST technique in the emergency department
- ◆ Determine the performance and image acquisition of a CT scanner and how that helps me in my daily work
- ◆ Identify which pathologies are more recommendable for MRI (Magnetic Resonance Imaging) studies
- ◆ Diagnose the pathologies of the cranium, celomic and thoracic cavity, orthopedic and abdominal pathologies in birds, small mammals and reptiles common in the small animal clinic

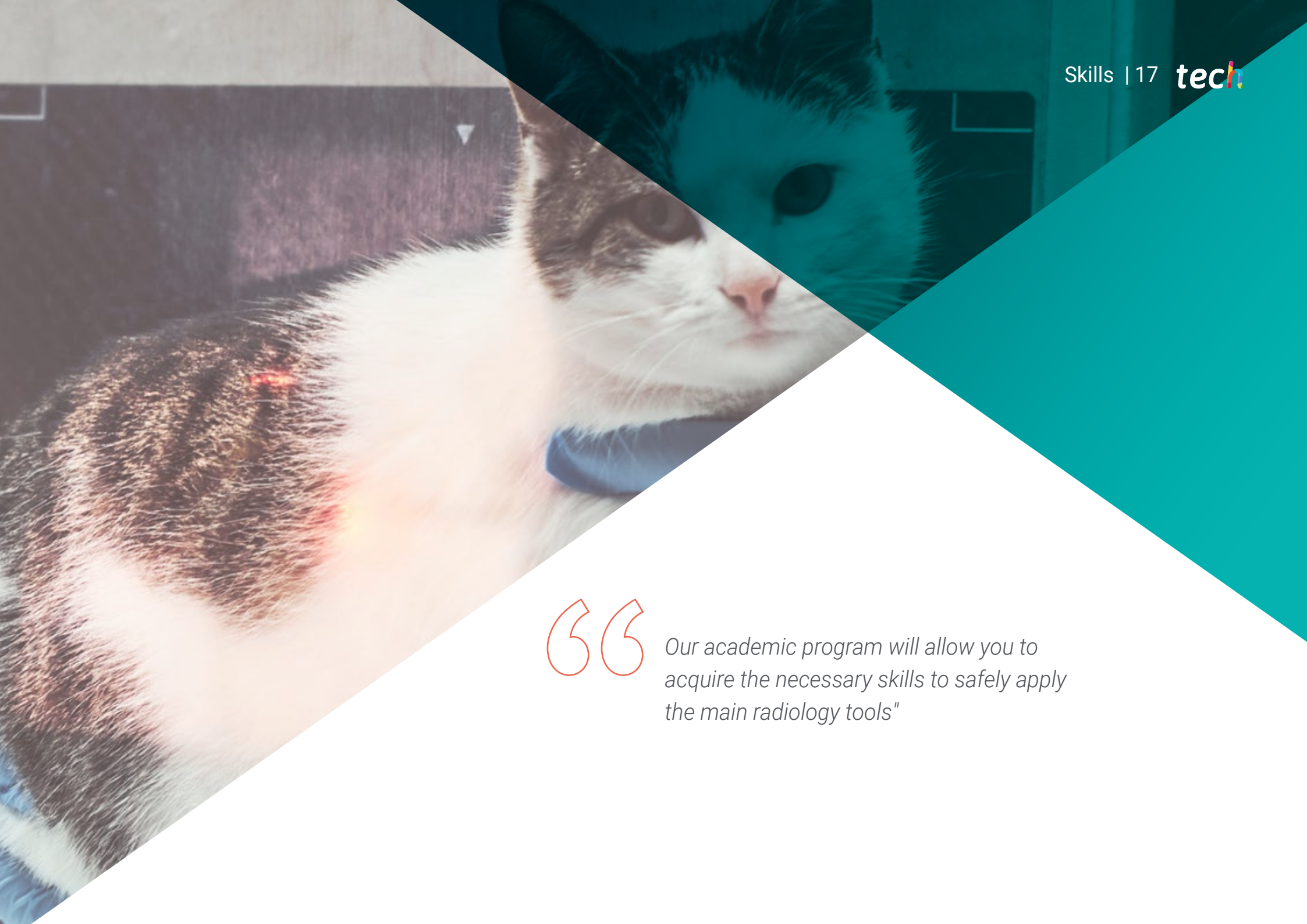

A training and professional growth pathway that will propel you towards greater competitiveness in the labor market"

03 Skills

After completing this Professional Master's Degree, students will have acquired the specific skills to develop professionally in the field of veterinary medicine, applying radiology techniques that will be useful for the diagnosis of possible pathologies.





“

Our academic program will allow you to acquire the necessary skills to safely apply the main radiology tools"

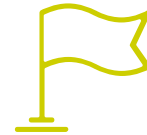
After completing this training, the professional will be able to:



General Skills

- ♦ Develop specific skills to successfully carry out the professional activity in the broad environment of diagnostic imaging
- ♦ Knowing the reality and daily practice of the veterinary hospital
- ♦ Attend veterinary emergencies using radiology tools to detect the pathologies of the animal





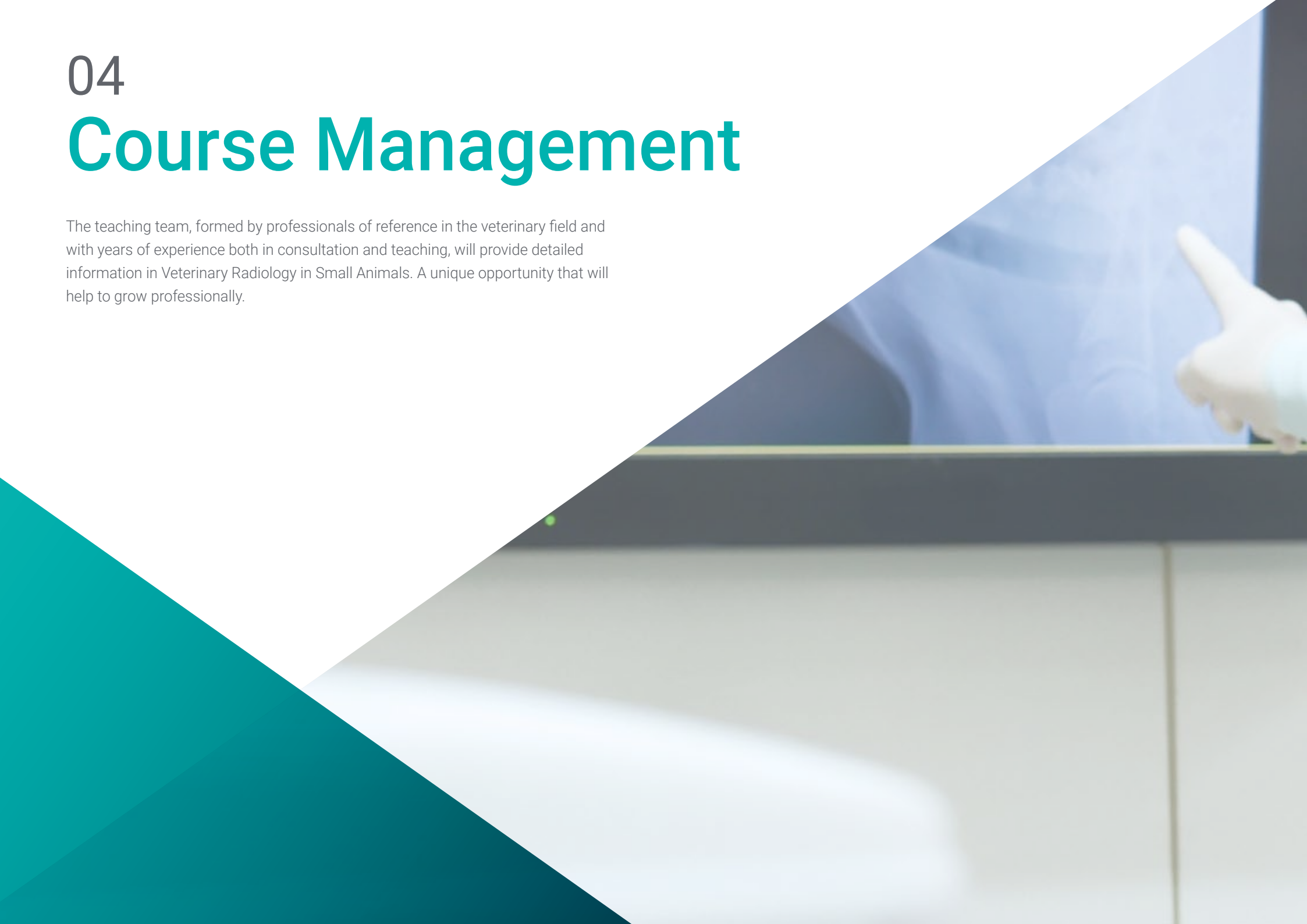Specific Skills

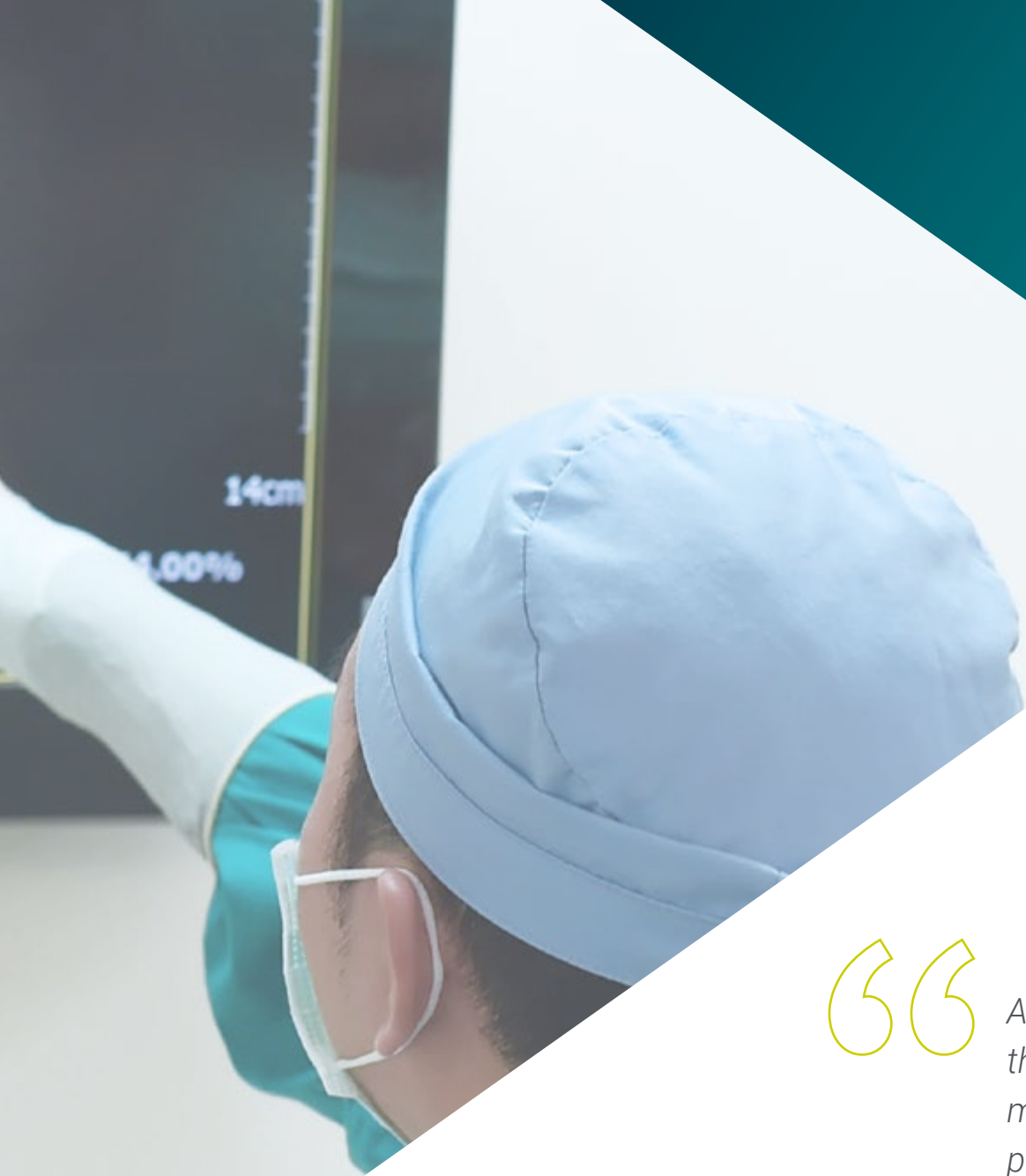- ♦ Safe handling of radiology equipment
- ♦ Perform an adequate radiological examination
- ♦ Recognize small animal diseases with appropriate images, but also with deficient images
- ♦ Perform radiographic evaluation of the cardiac chambers
- ♦ Understand the deficiency of radiological imaging and understand the need to order other complementary imaging tests
- ♦ Perform radiographs to evaluate the neurological system under sedation, using appropriate positioning accessories
- ♦ Use imaging to identify trauma problems
- ♦ Use diagnostic imaging methods in exotic animals
- ♦ Interpret radiological images
- ♦ Know the legal regulations for using radiology equipment
- ♦ Develop with responsibility the monitoring and supervision of their work, as well as communication skills within the essential teamwork

04

Course Management

The teaching team, formed by professionals of reference in the veterinary field and with years of experience both in consultation and teaching, will provide detailed information in Veterinary Radiology in Small Animals. A unique opportunity that will help to grow professionally.





“

At TECH you will have the opportunity to train with the best professionals in this branch of veterinary medicine, which will help you to reach the professional elite"

Management



Dr. Gómez Poveda, Bárbara

- ♦ Parque Grande Veterinary Clinic. General veterinary
- ♦ Veterinary emergencies Las Rozas, Madrid. Emergency and hospitalization service
- ♦ Barvet Veterinary at home Mobile Veterinary Director (Madrid)
- ♦ Parla Sur Veterinary Hospital. Emergency and hospitalization service
- ♦ Veterinary Degree. Complutense University of Madrid
- ♦ Postgraduate in Small Animal Surgery (GPCert SAS). Madrid Improve International
- ♦ Online postgraduate course in Small Animal Clinic. Autonomous University (Barcelona)

Professors

Dr. Guerrero Campuzano, María Luisa

- ◆ Director, veterinarian of exotic animals and small animals at the Petiberia Veterinary Clinic. Since 2010
- ◆ Degree in Veterinary Medicine from the University of Alfonso X el Sabio (2009).
- ◆ Specialist degree in exotic and wild animals: management, clinic and breeding in captivity by the Complutense University of Madrid
- ◆ Postgraduate Diploma in Surgery and Anesthesia from the Autonomous University of Barcelona 2014
- ◆ Seminar on anesthesia applied to the clinic of Oasis Wildlife Fuerteventura
- ◆ Co-author of the interactive clinical case on "Metabolic bone disease in reptiles" in the specialty of new companion animals, in the training platform of AVEPA Elearning
- ◆ Co-author of the scientific knowledge pill "Feeding in psittacine birds", of the AVEPA Elearning scientific knowledge platform
- ◆ Teacher of the course "Management and Clinic of Exotic Animals for Veterinary Technical Assistants", AMVET training
- ◆ Member of AVEPA and in the process of accreditation as an exotic animal specialist of the GMCAE

Dr. Conde Torrente, María Isabel

- ◆ Head of the Diagnostic Imaging and Cardiology Service at Alcor Veterinary Hospital. Currently
- ◆ Degree in Veterinary Medicine from the University of Santiago de Compostela in 2012 with a certified European degree
- ◆ Advanced Postgraduate Course in Diagnostic Imaging (Computerized Axial Tomography). TCESMD. 2019
- ◆ Postgraduate in Diagnostic Imaging (GPCert- DI) 2016
- ◆ Training courses on clinical and laboratory analysis for veterinarians at the Alberto Alcocer Veterinary Hospital
- ◆ Medical Director and head of the Advanced Diagnostic Imaging Service of Peñagrande Group. 2017-2019
- ◆ Head of the Diagnostic Imaging Service at Mejorada Veterinary Center. 2016-2017
- ◆ Responsible for diagnostic services at Alberto Alcocer Veterinary Hospital. 2013-2016

Dr. Moreno, Lorena

- ◆ Graduated in Veterinary Medicine from the Complutense University (Madrid) in 2012
- ◆ Postgraduate Course in Small Animal Surgery and Anesthesia at the UAB
- ◆ Currently taking a postgraduate course in Neurology for veterinarians on the web
- ◆ Senior Veterinarian, as Head Clinician, at Momo Veterinary Hospital (Madrid, Spain) since 2015
- ◆ Veterinarian at the Veterinary Hospital "Sierra Oeste" in San Martín de Valdeiglesias (Madrid). 2014-2015

Dr. García Montero, Javier

- ♦ In Charge of Trauma and Orthopedics, Surgery and Anesthesia. Veterinary Hospital Cruz Verde (Alcazar de San Juan). Since 2019
- ♦ Degree in Veterinary, Faculty of Veterinary Medicine, Córdoba 2009 -2015.
- ♦ Studying the Postgraduate Course in Soft Tissue Surgery and Anesthesia in Small Animals by the Autonomous University (Barcelona)
- ♦ Certificate of Treatment of Fractures in Toy Dogs and Cats. UCM Online University, 2019
- ♦ Tibial Plateau Leveling Workshop
- ♦ Theoretical and practical sessions on fracture management in the feline patient
- ♦ Theoretical and practical seminar on carpal and tarsal arthrodesis
- ♦ Joint Instability Workshop

Dr. Moliní Aguiar, Gabriela

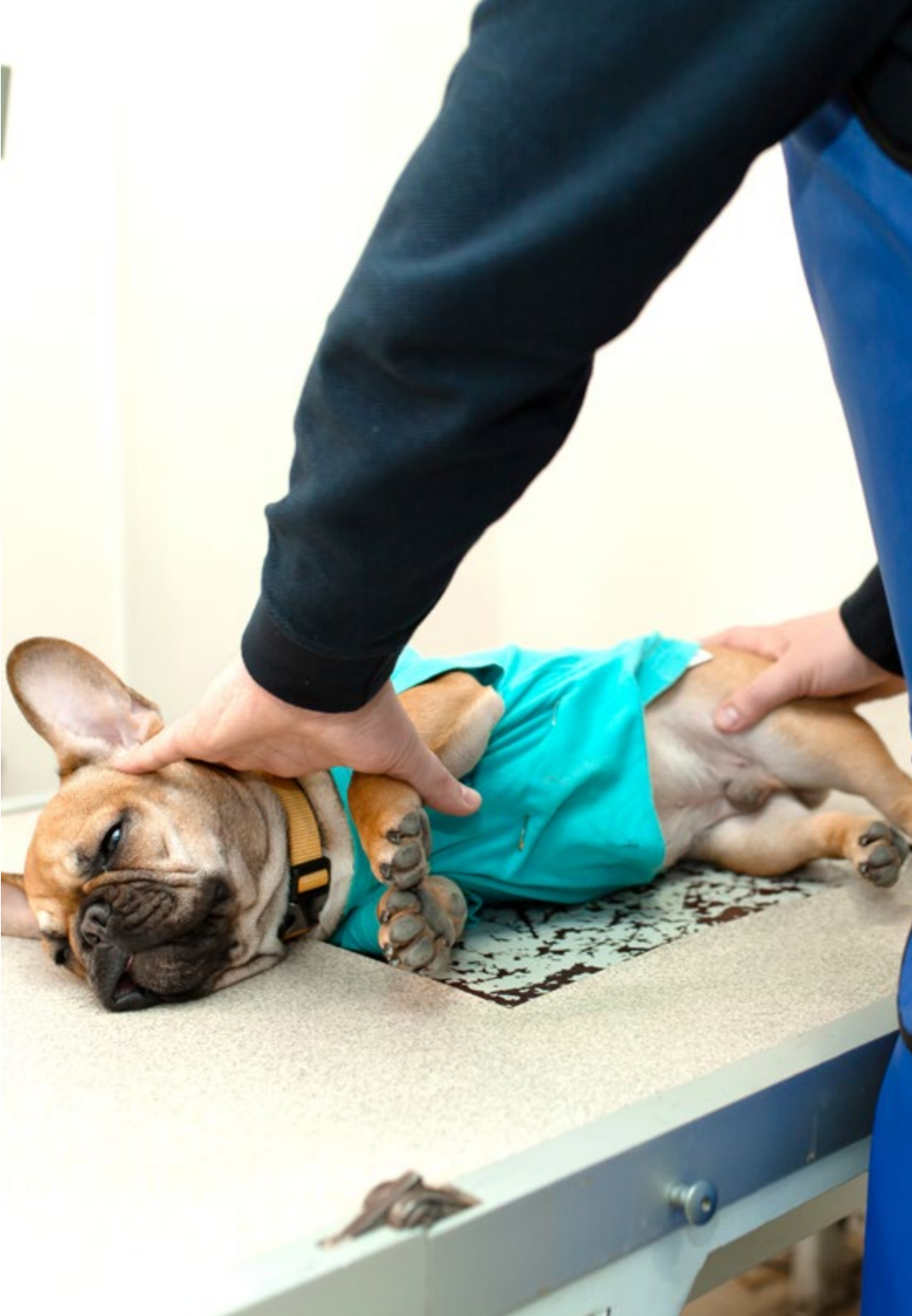- ♦ Head of the Radiology Department of the Petiberia Veterinary Clinic. Since 2018
- ♦ Responsible for the anesthesia service at Petiberia Veterinary Clinic. Since 2017
- ♦ Graduated in Veterinary Medicine from the Complutense University of Madrid in 2014
- ♦ Neurology in the Feline and Canine patient. Novotech. November 2020
- ♦ Internal medicine in the feline patient. Novotech. November 2020
- ♦ Course of radiological interpretation in small animals of the Veterinary College of Madrid. June 2020
- ♦ Master in Microbiology and Parasitology: research and development. September 2015

Dr. Lázaro González, María

- ♦ Degree in Veterinary Medicine from the Alfonso X El Sabio University Madrid, 2018
- ♦ GPCert in feline medicine 2020
- ♦ Postgraduate in Diagnostic Imaging
- ♦ Postgraduate in Feline Medicine
- ♦ Internship in animal anatomy during the veterinary degree program
- ♦ Responsible for the emergency, internal medicine, radiology and ultrasound services at Gattos Hospital Feline Clinical Center (2018-2020)

Dr. Gandía, Anaí

- ♦ Veterinarian at Veterinary Clinic El Pinar (Navalcarnero, Madrid). Since 2020
- ♦ Graduated in Veterinary Medicine from Alfonso X El Sabio University in 2020
- ♦ Collaboration as a student in the Neurology Service of the HCV of the UAX in the area of small animals. 2019-2020
- ♦ Currently attending the International Improvement Postgraduate Course on "Small Animal Surgery: soft tissues, traumatology and neurosurgery"
- ♦ Colvema course "Diagnosis of alopecia in the dog" September 2020
- ♦ Colvema course "Canine cutaneous mastocytoma, how should we act?" November 2020
- ♦ Leganés Norte Veterinary Clinic, as VCT. 2017-2018



Dr. Nieto Aldeano, Damián

- ♦ Responsible for the Radiology service. Las Tablas and Diagnosfera (Madrid)
- ♦ Graduated in 2013 from the University of Murcia. Academic Training
- ♦ General Practitioner Certificate in Diagnostic Imaging by the ESVPS in 2018
- ♦ Intern in Veterinary Hospital "Città di Pavia" in Pavia (Italy)
- ♦ Radiology and ultrasound, internal medicine, interpretation of analytical tests, hospitalization, anesthesia, on-site and off-site emergencies. Clinics and hospitals in the country
- ♦ Course in abdominal ultrasound in small animals
- ♦ Course in Cytology of internal organs, eyes, ears and ganglia

Dr. Calzado Sánchez, Isabel

- ♦ Veterinarian specialized in exotic animals. HV Exotic Animals 24h and HV Gwana Vet. General veterinarian in hospitals specializing in exotic animals. Internal medicine, hospitalization, emergency and laboratory services
- ♦ Small animal veterinarian. CV Sansepet, HV Miramadrid. General veterinarian in dog and cat clinics. Internal medicine, preventive medicine, diagnostic imaging and in charge of the exotic animal area
- ♦ Veterinary Degree. Alfonso X el Sabio University
- ♦ General Practitioner in exotic animals. ISVPS Improve International

05

Structure and Content

The contents of this Professional Master's Degree in Veterinary Radiology in Small Animals have been designed by a team of experts, backed by their years of experience. In this way, they have been in charge of programming a totally up-to-date syllabus aimed at the professional of the 21st century, who demands high quality training and knowledge of the main innovations in the field.

“

We put at your disposal a very complete syllabus, totally up-to-date and with the main novelties on the tools of veterinary radiology”

Module 1. Ionizing Radiation for Diagnostic Purposes

- 1.1. General Principles
 - 1.1.1. Electron Acceleration
 - 1.1.2. Electrical Current Intensity
 - 1.1.3. The Anode, Where the Anions Collide
- 1.2. Photon Formation with Diagnostic Effects
 - 1.2.1. Types of Photons
 - 1.2.2. Photon Energy
 - 1.2.3. Orientation of Emitted Photons
 - 1.2.4. Scattering of the Energy Generated by Photons
- 1.3. Scattered Radiation
 - 1.3.1. Anode Dispersion
 - 1.3.2. Patient Dispersion
 - 1.3.3. Implications for Clinical Imaging
 - 1.3.4. Dispersion of Objects in the Radiodiagnostic Room
- 1.4. The Formation of Radiological Imaging
 - 1.4.1. Radiological Chassis
 - 1.4.2. Radiological Films
 - 1.4.3. RC Processing
 - 1.4.4. DR Processing
- 1.5. Radiological Film Processing
 - 1.5.1. Development in Automatic Processors and Development Vats
 - 1.5.2. Liquid Recycling
 - 1.5.3. Processing with Digital Chassis
 - 1.5.4. Digital Direct Processing
- 1.6. Factors Affecting Radiological Imaging
 - 1.6.1. Time
 - 1.6.2. Voltage
 - 1.6.3. Amperage
- 1.7. Alterations in the Perception of the Radiological Image
 - 1.7.1. Pareidolia
 - 1.7.2. Magnification
 - 1.7.3. Distortion
- 1.8. Radiological Interpretation
 - 1.8.1. Systematization of Interpretation
 - 1.8.2. Validity of the Image Obtained
 - 1.8.3. Differences between Tissues
 - 1.8.4. Identification of Healthy Organs
 - 1.8.5. Identification of Radiological Alterations
 - 1.8.6. Typical Diseases of the Different Anatomical Regions
- 1.9. Limiting Factors in Radiological Diagnosis, Time
 - 1.9.1. Regions in Motion
 - 1.9.2. Still Regions
 - 1.9.3. Fuzziness
 - 1.9.4. Anesthesia in Radiology
 - 1.9.5. Radiological Positioners
 - 1.9.6. Anatomical Regions in Which Time Has To Be Taken into Consideration
- 1.10. Limiting Factors in Radiological Diagnosis, Voltage
 - 1.10.1. Density of the Radiographic Region
 - 1.10.2. Contrast
 - 1.10.3. Sharpness
 - 1.10.4. Anatomical Regions in Which the Energy of Photons Must Be taken into Consideration

Module 2. Radioprotection

- 2.1. Radiation Physics
 - 2.1.1. Atomic Structure
 - 2.1.2. Interaction of Radiation with Matter
 - 2.1.3. Radiological Units
- 2.2. X-ray Equipment Characteristics
 - 2.2.1. Tube Elements
 - 2.2.2. Devices
 - 2.2.3. Radiation Produced
 - 2.2.4. Radiological Imaging
- 2.3. Measurement of Ionizing Radiation
 - 2.3.1. Personal Dosimetry
 - 2.3.2. Environmental Dosimetry
- 2.4. Detectors Used in Radiodiagnostic Installations
 - 2.4.1. General Principles
 - 2.4.2. Detectors in the Room
 - 2.4.3. Detectors Outside the Room
 - 2.4.4. Personnel Detectors
- 2.5. Radiobiology
 - 2.5.1. Cellular Response to Ionizing Radiation
 - 2.5.2. Systemic and Organic Response
 - 2.5.3. Diseases Caused by Radiation
- 2.6. Protection Against Ionizing Radiation
 - 2.6.1. General Criteria
 - 2.6.2. Operational Radiation Protection
 - 2.6.3. ALARA Principle
- 2.7. Specific Radiological Protection in Radiodiagnostic
 - 2.7.1. Personal Protectors
 - 2.7.2. Shielding of the Room
 - 2.7.3. Distance
 - 2.7.4. Workload

- 2.8. General Requirements for a Radiodiagnostic Facility
 - 2.8.1. Location
 - 2.8.2. Power Supply
 - 2.8.3. Shielding
- 2.9. Quality Control of the Radiodiagnostic Installation
 - 2.9.1. Shielding
 - 2.9.2. The X-ray Emission Tank
 - 2.9.3. The Collimator
 - 2.9.4. The X-ray Table
 - 2.9.5. Lead Aprons
- 2.10. Legislation
 - 2.10.1. European Legislation
 - 2.10.2. Legislation of the Room
 - 2.10.3. Medical Checkups
 - 2.10.4. Other Considerations

Module 3. Radiodiagnosis of the Cardiovascular System

- 3.1. Positioning in Cardiovascular Radiological Diagnosis
 - 3.1.1. Right Lateral Projection
 - 3.1.2. Dorsoventral Projection
 - 3.1.3. Differences with Other Projections
- 3.2. Physiological Radiological Imaging of the Cardiovascular System
 - 3.2.1. Cardiac Silhouette
 - 3.2.2. Cardiac Cameras
 - 3.2.3. Large Vessels
- 3.3. Altered Radiological Image of the Cardiovascular System
 - 3.3.1. Cardiac Size Alteration
 - 3.3.2. Vascular Alteration
 - 3.3.3. Radiographic Signs of Heart Failure
- 3.4. Acquired Heart Diseases I
 - 3.4.1. Mitral Degenerative Disease
 - 3.4.2. Canine Cardiomyopathy
 - 3.4.3. Pericardial Diseases

- 3.5. Acquired Heart Diseases II
 - 3.5.1. Feline Cardiomyopathies
 - 3.5.2. Dirofilariasis
 - 3.5.3. Systemic Diseases with Cardiac Implications
- 3.6. Oncology
 - 3.6.1. Neoplasia of the Right Atrium
 - 3.6.2. Cardiac-based Neoplasm
 - 3.6.3. Congenital Heart Diseases
- 3.7. Patent Ductus Arteriosus
 - 3.7.1. Introduction
 - 3.7.2. Existing Forms
 - 3.7.3. Radiological Characteristics
 - 3.7.4. CAP with D-I Shunt
- 3.8. Vascular Ring Anomalies
 - 3.8.1. Introduction
 - 3.8.2. Types
 - 3.8.3. Radiological Characteristics
- 3.9. Other Congenital Diseases
 - 3.9.1. Pulmonary Stenosis
 - 3.9.2. Atrioventricular Septal Defect
 - 3.9.3. Tetralogy of Fallot
 - 3.9.4. Aortic Stenosis
 - 3.9.5. Interatrial Septal Defect
 - 3.9.6. Mitral Dysplasia
 - 3.9.7. Tricuspid Dysplasia
 - 3.9.8. Microcardia
- 3.10. Radiological Diagnosis of Pericardial Diseases
 - 3.10.1. Radiological Diagnosis of Pericardial Diseases
 - 3.10.1.1. Pericardial Effusion
 - 3.10.1.2. Introduction
 - 3.10.1.3. Radiological Characteristics
 - 3.10.2. Peritoneopericardial Diaphragmatic Hernia
 - 3.10.2.1. Introduction
 - 3.10.2.2. Radiological Characteristics

Module 4. Radiodiagnostics of the Respiratory System and Other Intrathoracic Structures

- 4.1. Positioning for Thorax Radiology
 - 4.1.1. Ventrodorsal and Dorsoventral Positioning
 - 4.1.2. Right and Left Laterolateral Positioning
- 4.2. Physiological Imaging of the Thorax
 - 4.2.1. Trachea Physiological Imaging
 - 4.2.2. Mediastinum Physiological Imaging
- 4.3. Pathologic Imaging in Thoracic Radiology
 - 4.3.1. Alveolar Pattern
 - 4.3.2. Bronchial Pattern
 - 4.3.3. Interstitial Pattern
 - 4.3.4. Vascular Pattern
- 4.4. Radiological Diagnosis of Acquired Pulmonary Diseases I
 - 4.4.1. Structural Pathologies
 - 4.4.2. Infectious Pathologies
- 4.5. Radiological Diagnosis of Acquired Pulmonary Diseases II
 - 4.5.1. Inflammatory Pathology
 - 4.5.2. Neoplasms
- 4.6. Feline-specific Thoracic Radiology
 - 4.6.1. Radiology of the Heart in the Cat
 - 4.6.1.1. Radiographic Anatomy of the Heart
 - 4.6.1.2. Radiographic Diagnosis of Cardiac Pathologies
 - 4.6.2. Radiology of the Thoracic Wall and Diaphragm of the Cat
 - 4.6.2.1. Anatomy of the Thoracic Cage
 - 4.6.2.2. Radiographic Diagnosis of Thoracic Wall and Diaphragm Pathologies
 - 4.6.2.2.1. Congenital Skeletal Malformations
 - 4.6.2.2.2. Fractures
 - 4.6.2.2.3. Neoplasms

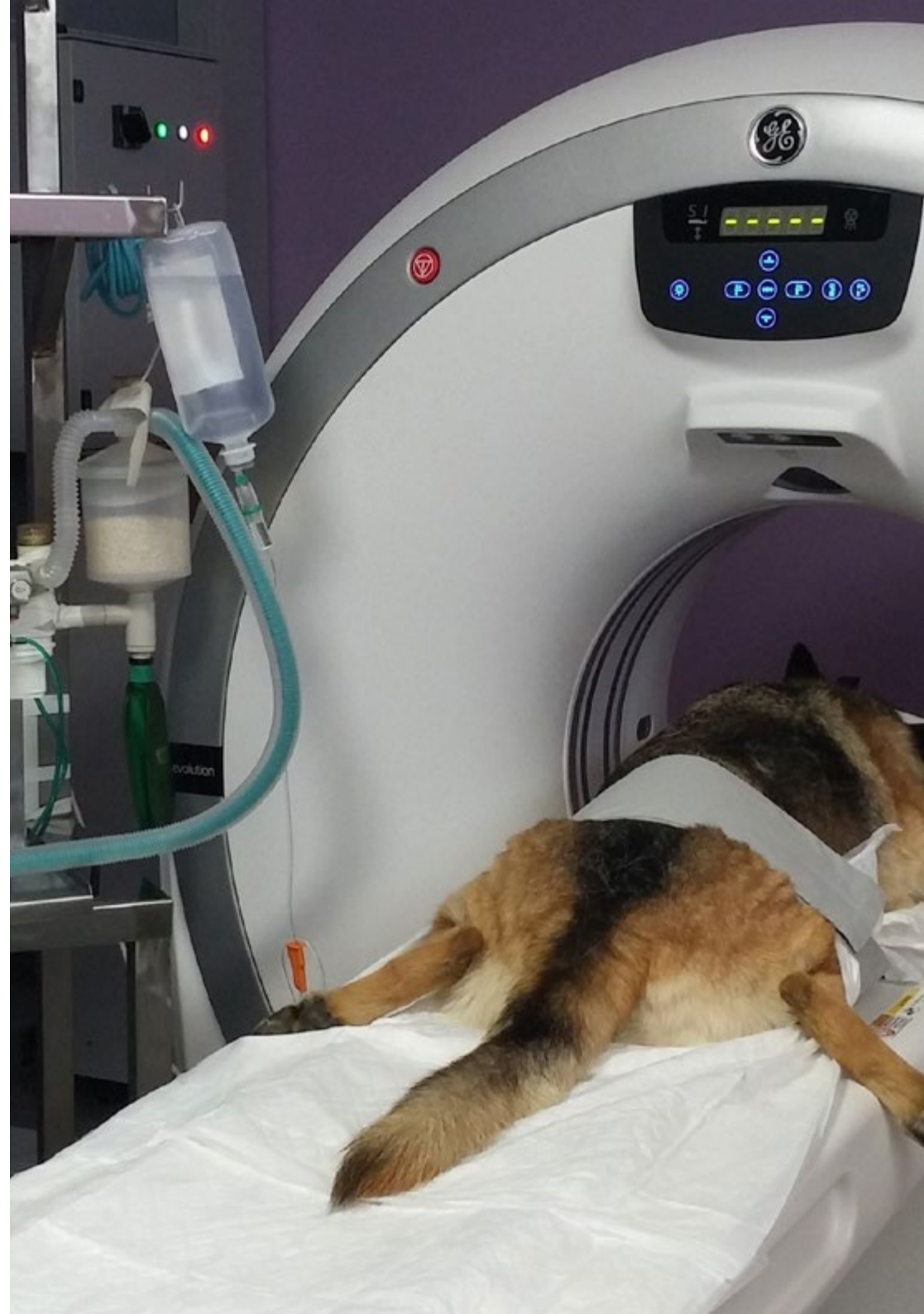- 4.6.2.2.4. Alterations of the Diaphragm
- 4.6.3. Radiology of the Pleura and Pleural Cavity of the Cat
 - 4.6.3.1. Radiographic Diagnosis of the Pleura and Pleural Cavity Pathologies
 - 4.6.3.1.1. Pleural Effusion
 - 4.6.3.1.2. Pneumothorax
 - 4.6.3.1.3. Hydropneumothorax
 - 4.6.3.1.4. Pleural Masses
- 4.6.4. Radiology of the Cat Mediastinum
 - 4.6.4.1. Radiographic Anatomy of the Mediastinum
 - 4.6.4.2. Radiographic Diagnosis of Pathologies of the Mediastinum and the Organs it Contains
 - 4.6.4.2.1. Pneumomediastinum
 - 4.6.4.2.2. Mediastinal Masses
 - 4.6.4.2.3. Esophageal Diseases
 - 4.6.4.2.4. Tracheal Diseases
- 4.6.5. Pulmonary Radiology of the Cat
 - 4.6.5.1. Normal Pulmonary Radiologic Anatomy
 - 4.6.5.2. Radiographic Diagnosis of Pulmonary Pathologies
 - 4.6.5.2.1. Pulmonary Patterns
 - 4.6.5.2.2. Decreased Pulmonary Opacity
- 4.7. Radiology of the Mediastinum
 - 4.7.1. Radiographic Anatomy of the Mediastinum
 - 4.7.2. Mediastinal Effusion
 - 4.7.3. Pneumomediastinum
 - 4.7.4. Mediastinal Masses
 - 4.7.5. Mediastinal Deviation
- 4.8. Congenital Thoracic Diseases
 - 4.8.1. Patent Ductus Arteriosus
 - 4.8.2. Pulmonary Stenosis.
 - 4.8.3. Aortic Stenosis
 - 4.8.4. Ventricular Septal Defect
 - 4.8.5. Tetralogy of Fallot

- 4.9. Oncology
 - 4.9.1. Pleural Masses
 - 4.9.2. Mediastinal Masses
 - 4.9.3. Cardiac Tumors
 - 4.9.4. Pulmonary Tumors
- 4.10. Radiology of the Thoracic Cage
 - 4.10.1. Anatomy Radiologic of the Thoracic Cage
 - 4.10.2. Radiological Alterations of the Ribs
 - 4.10.3. Radiological Alterations of the Sternum

Module 5. Radiodiagnosis of the Digestive System

- 5.1. Radiological Diagnosis of the Esophagus
 - 5.1.1. Radiology of the Normal Esophagus
 - 5.1.2. Radiology of the Pathologic Esophagus
- 5.2. Radiology of the Stomach
 - 5.2.1. Radiology and Positioning for the Diagnosis of Gastric Diseases
 - 5.2.2. Volvulus of Stomach
 - 5.2.3. Hiatal Hernias
 - 5.2.4. Gastric Tumors
 - 5.2.5. Foreign Bodies
- 5.3. Small Bowel Radiology
 - 5.3.1. Duodenum
 - 5.3.2. Jejunum
 - 5.3.3. Ileum
- 5.4. Iliocecal Valve Radiology
 - 5.4.1. Physiological Imaging of the Valve
 - 5.4.2. Pathological Imaging
 - 5.4.3. Common Pathologies
- 5.5. Colon Radiology
 - 5.5.1. Radiological Anatomy of the Colon
 - 5.5.2. Oncologic Diseases of the Colon
 - 5.5.3. Megacolon

- 5.6. Rectal Radiology
 - 5.6.1. Anatomy
 - 5.6.2. Diverticula
 - 5.6.3. Neoplasms
 - 5.6.4. Displacements
- 5.7. Radiological Imaging of Perineal Hernia
 - 5.7.1. Anatomical Structuring
 - 5.7.2. Abnormal Radiological Images
 - 5.7.3. Contrasts
- 5.8. Radiological Oncology of Perineal Region
 - 5.8.1. Structures Affected
 - 5.8.2. Lymph Node Examination
- 5.9. Radiological Contrasts Applied to the Digestive System
 - 5.9.1. Barium Swallowing
 - 5.9.2. Barium Intake
 - 5.9.3. Nemogastrography
 - 5.9.4. Barium Enema and Double Contrast Enema
 - 5.9.5. Radiological Assessment of the Surgical Progression of Diseases of the Stomach
- 5.10. Radiological Assessment of the Surgical Progression of Diseases of the Stomach
 - 5.10.1. Future Dehiscence
 - 5.10.2. Transit Alterations
 - 5.10.3. Surgical Reintervention Decision-Making
 - 5.10.4. Other complications



Module 6. Radiodiagnosis of the Rest of Abdominal Structures

- 6.1. Hepatic Radiological Diagnosis
 - 6.1.1. Radiological Imaging of the Physiological Liver
 - 6.1.2. Liver Disease
 - 6.1.3. Radiological Examination of the Biliary Tract
 - 6.1.4. Portosystemic Shunts
 - 6.1.5. Oncology
- 6.2. Pancreatic Radiology
 - 6.2.1. Radiological Imaging of the Physiological Pancreas
 - 6.2.2. Pancreatic Disease
 - 6.2.3. Oncology
- 6.3. Spleen Radiology
 - 6.3.1. Physiological Radiological Imaging of the Spleen
 - 6.3.2. Diffuse Splenomegaly
 - 6.3.3. Focal Splenomegaly
- 6.4. Radiology of the Excretory System
 - 6.4.1. Renal Radiology
 - 6.4.2. Radiology of the Ureters
 - 6.4.3. Radiology of the Bladder
 - 6.4.4. Radiology of the Urethra
 - 6.4.5. Oncology of the Excretory System
- 6.5. Radiology of the Genital System
 - 6.5.1. Normal Radiological Imaging of the Female Genital System
 - 6.5.2. Pathological Radiological Imaging of Female Genital System
 - 6.5.3. Normal Radiological Imaging of the Male Genital System
 - 6.5.4. Pathologic Radiological Imaging of the Male Genital System
- 6.6. Radiology of the Retroperitoneal Space
 - 6.6.1. Normal Appearance of the Retroperitoneum
 - 6.6.2. Retroperitonitis
 - 6.6.3. Masses in the Retroperitoneal Space

- 6.7. Radiology of the Peritoneum
 - 6.7.1. Peritoneal Cavity Pathology
 - 6.7.2. Retroperitoneal Space
 - 6.7.3. Abdominal Masses
- 6.8. Radiology of the Adrenal Glands
 - 6.8.1. Normal Appearance of the Adrenal Gland
 - 6.8.2. Techniques and Benign/Malignant Diagnosis
 - 6.8.3. Frequent Adrenal Injuries
- 6.9. Oncologic Radiology
 - 6.9.1. Detection of Clinically Undetectable Tumors
 - 6.9.2. Primary Masses vs. Metastasis
 - 6.9.3. Radiological Signs of Malignancy
- 6.10. Radiology of Diseases of the Abdominal Wall and Abdominal Boundaries
 - 6.10.1. Hernias and Diaphragmatic Diseases
 - 6.10.2. Abdominal Hernias
 - 6.10.3. Perineal Hernias
 - 6.10.4. Pelvic Fractures
 - 6.10.5. Obliterating Flow Diseases

Module 7. Radiological Diagnosis in Neurology

- 7.1. Radiological Anatomy
 - 7.1.1. Structures Assessable by Radiology
 - 7.1.1.1. Normal Radiological Anatomy of the Spine
 - 7.1.1.2. Normal Radiological Anatomy of the Skull and its Structures
- 7.2. Radiological Examination of the Spine
 - 7.2.1. C1-C6
 - 7.2.2. T1-T13
 - 7.2.3. L1-L7
 - 7.2.4. S1-Cd
- 7.3. Contrast Examination
 - 7.3.1. Cisternal Myelography
 - 7.3.2. Lumbar Myelography
 - 7.3.3. Pathological Alterations Observed by Myelography

- 7.4. Diagnosis of Vascular Pathologies
 - 7.4.1. Vascular Pathologies: How Far Can We Go with Conventional Radiology
 - 7.4.2. Assessment of Vascular Pathologies by Contrast Techniques
 - 7.4.3. Assessment of Vascular Pathologies by Other Imaging Techniques
- 7.5. Cerebral and Meningeal Malformations
 - 7.5.1. Hydrocephalus
 - 7.5.2. Meningocele
- 7.6. Inflammatory Pathology
 - 7.6.1. Infectious
 - 7.6.2. Non-infectious
 - 7.6.3. Disc Spondylitis
- 7.7. Degenerative Pathologies
 - 7.7.1. Degenerative Disc Disease
 - 7.7.2. Wobbler Syndrome
 - 7.7.3. Lumbosacral Instability, Cauda Equina Syndrome
- 7.8. Spiral Trauma
 - 7.8.1. Pathophysiology
 - 7.8.2. Fractures
- 7.9. Oncology
 - 7.9.1. Primary Neoplastic Diseases
 - 7.9.2. Secondary Metastatic Diseases
- 7.10. Other Neurological Diseases
 - 7.10.1. Metabolic
 - 7.10.2. Nutritional
 - 7.10.3. Congenital

Module 8. Orthopedic Radiological Diagnosis I

- 8.1. The Growth Plate
 - 8.1.1. Organization of the Growth Plate and its Impact on Radiological Imaging
 - 8.1.2. Blood Supply of the Growth Plate
 - 8.1.3. Structure and Function of the Growth Plate Cartilaginous Components
 - 8.1.3.1. Reserve Zone
 - 8.1.3.2. Proliferative Zone
 - 8.1.3.3. Hypertrophic Zone
 - 8.1.4. Bone Components (Metaphysis)
 - 8.1.5. Fibrous and Fibrocartilaginous Components
 - 8.1.6. Radiological Imaging of the Growth Plate at Different Stages of Growth
 - 8.1.6.1. Epiphysiolysis
 - 8.1.6.2. Other Growth Disorders
- 8.2. Fracture Repair
 - 8.2.1. Radiological Response of Traumatized Bone
 - 8.2.2. Phased Fracture Repair
 - 8.2.2.1. Inflammatory Phase
 - 8.2.2.2. Repair Phase
 - 8.2.2.3. Remodelling Phase
 - 8.2.2.4. Callus formation
 - 8.2.2.5. Fracture Healing
 - 8.2.2.6. First Intention Repair
 - 8.2.2.7. Second Intention Repair
 - 8.2.2.8. Clinical Union
 - 8.2.2.9. Clinical Union Ranges
- 8.3. Fracture Complications
 - 8.3.1. Delayed Union
 - 8.3.2. Non-union
 - 8.3.3. Bad Union
 - 8.3.4. Osteomyelitis
- 8.4. Radiologic Imaging of Arthritis and Polyarthritis
 - 8.4.1. Types of Arthritis and Polyarthritis
 - 8.4.2. Clinical Diagnosis
 - 8.4.3. Differential Diagnosis Radiology
- 8.5. Radiological Imaging of Osteoarthritis
 - 8.5.1. Etiology
 - 8.5.2. Radiological Diagnosis
 - 8.5.3. Prognosis According to Radiological Imaging

- 8.6. Decision-making in Traumatology and Orthopedics Based on Radiologic Diagnosis
 - 8.6.1. Fulfilled Clinical Function
 - 8.6.2. Implant Ruptures
 - 8.6.3. Implant Bends
 - 8.6.4. Implant Migrates
 - 8.6.5. Rejection
 - 8.6.6. Infections
 - 8.6.7. Thermal Interference
- 8.7. Radiology of Orthopedic Diseases
 - 8.7.1. Radiology of Osteochondritis Dissecans
 - 8.7.2. Panosteitis
 - 8.7.3. Retained Cartilaginous Nucleus
 - 8.7.4. Hypertrophic Osteodystrophy
 - 8.7.5. Craniomandibular Osteopathy
 - 8.7.6. Bone Tumors
 - 8.7.7. Other Bone Diseases
- 8.8. Radiology of Hip Dysplasia
 - 8.8.1. Physiological Hip Radiology
 - 8.8.2. Pathological Hip Radiology
 - 8.8.3. Gradation of Hip Dysplasia
 - 8.8.4. Surgical Treatments for Hip Dysplasia
 - 8.8.5. Clinical/Radiographic Progression of Hip Dysplasia
- 8.9. Radiology of Elbow Dysplasia
 - 8.9.1. Physiological Elbow Radiology
 - 8.9.2. Pathological Elbow Radiology
 - 8.9.3. Types of Elbow Dysplasia
 - 8.9.4. Surgical Treatments for Elbow Dysplasia
 - 8.9.5. Clinical/Radiographic Progression of Elbow Dysplasia
- 8.10. Radiology of the Knee
 - 8.10.1. Radiology of Anterior Cruciate Ligament Rupture
 - 8.10.1.1. Surgical Treatment of Anterior Cruciate Ligament Rupture
 - 8.10.2. Radiology of Patellar Dislocation
 - 8.10.2.1. Gradation of Patellar Dislocation
 - 8.10.2.2. Surgical Treatment of Patellar Dislocation

Module 9. Orthopedic Radiological Diagnosis II

- 9.1. Anatomy Radiology of the Pelvis
 - 9.1.1. General Considerations
 - 9.1.2. Radiologic Assessment of Stable Hip Fractures
 - 9.1.3. Surgical Radiological Indication
 - 9.1.3.1. Intra-articular Fracture
 - 9.1.3.2. Closure of the Pelvic Canal
 - 9.1.3.3. Joint Instability of a Hemipelvis
 - 9.1.4. Fracture Separation of the Sacro-Iliac Joint
 - 9.1.5. Fractures of the Acetabulum
 - 9.1.6. Fracture of the Ilium
 - 9.1.7. Ischial Fractures
 - 9.1.8. Pubic Symphysis Fractures
 - 9.1.9. Fractures of the Ischial Tuberosity
- 9.2. Radiological Imaging of Femur Fractures
 - 9.2.1. Proximal Femoral Fractures
 - 9.2.2. Fractures of the Medium Third of the Femur
 - 9.2.3. Fractures of the Distal Third of the Femur
- 9.3. Radiological Imaging of Tibial Fractures
 - 9.3.1. Fractures of the Proximal Third
 - 9.3.2. Fractures of the Middle Third of the Tibia
 - 9.3.3. Fractures of the Distal Third of the Tibia
 - 9.3.4. Fractures of the Tibial Malleoli
- 9.4. Anterior Member
 - 9.4.1. Radiological Imaging of the Scapula Fractures
 - 9.4.2. Radiological Imaging of the Humerus Fractures
 - 9.4.3. Radiological Imaging of the Radius and Ulnar Fractures
- 9.5. Fractures of the Maxilla and Mandible, Radiological Imaging of the Skull
 - 9.5.1. Jaw Radiology
 - 9.5.1.1. Rostral Jaw
 - 9.5.1.2. Dental Radiology
 - 9.5.1.3. Temporomandibular Joint (TMJ)

- 9.5.2. Radiology of the Maxilla
 - 9.5.2.1. Dental Radiology
 - 9.5.2.2. Radiology of the Maxilla
- 9.5.3. Radiology to the Paranasal Sinus
- 9.5.4. Radiology of the Skull
- 9.5.5. Oncology
- 9.6. Radiology of Fractures and Other Alterations Resulting in Incongruence of the Articular Surface
 - 9.6.1. Fractures Affecting the Growth Nucleus
 - 9.6.2. Classification of the Epiphysis Based on its Type
 - 9.6.3. Classification of Slipped or Split Fractures Involving the Growth Nucleus and Adjacent Epiphyseal Metaphysis
 - 9.6.4. Clinical Assessment and Treatment of Damage to Nucleus Growth
 - 9.6.5. Radiology of Joint Fractures in Adult Animals
- 9.7. Joint Dislocations, Radiology
 - 9.7.1. Radiological Positioning
 - 9.7.2. Nomenclature
 - 9.7.3. Traumatic Dislocations
 - 9.7.4. Scapulohumeral Instability
- 9.8. Interventional Radiology in Traumatology
 - 9.8.1. Radiology of the Fractures Affecting the Growth Nucleus
 - 9.8.2. Radiology of Fractures Involving the Epiphysis based on Their Type
 - 9.8.3. Radiology of Slipped or Split Fractures Involving the Growth Nucleus, Epiphysis and Adjacent Metaphysis
 - 9.8.4. Radiology of Joint Fractures in Adult Animals
- 9.9. Radiology of Muscular, Tendinous and Ligamentous Diseases
 - 9.9.1. Radiology of Muscular Diseases
 - 9.9.2. Radiology of Tendinous and Ligamentous Diseases
 - 9.9.3. Other Alternatives for Diagnostic Imaging of these Pathologies
- 9.10. Radiology of Metabolic and Nutritional Disorders
 - 9.10.1. Introduction
 - 9.10.2. Radiologic Imaging in Secondary Nutritional Hyperparathyroidism
 - 9.10.3. Radiologic Imaging in Secondary Renal Hyperparathyroidism
 - 9.10.4. Radiological Imaging in Hypervitaminosis A
 - 9.10.5. Radiologic Imaging in Pituitary Dwarfism

Module 10. Other Diagnostic Imaging Methods. Diagnosis in Other Species. Exotic Animals

- 10.1. Ultrasound Diagnosis
 - 10.1.1. Abdominal Cavity Ultrasound
 - 10.1.1.1. Introduction to The Ultrasound Method
 - 10.1.1.2. Examination Routine and Protocol for Performing the Ultrasound Examination
 - 10.1.1.3. Identification of the Main Abdominal Structures
 - 10.1.1.4. ECOFAST Technique
 - 10.1.1.5. Abdominal Cavity Pathologies
 - 10.1.2. Cardiac Ultrasound
 - 10.1.2.1. Introduction to Cardiac Study Doppler Ultrasound
 - 10.1.2.2. Examination Protocol
 - 10.1.2.3. B-Mode and M-Mode
 - 10.1.2.4. Acquired Cardiac Diseases
 - 10.1.2.5. Congenital Cardiac Diseases
 - 10.1.2.6. Pericardium
 - 10.1.3. Ultrasound of the Musculoskeletal System
 - 10.1.3.1. Scanning Technique
 - 10.1.3.2. Assessment of Muscle Fibers and Tendons
 - 10.1.3.3. Ultrasound Assessment of the Bone
 - 10.1.3.4. Ultrasound Assessment of Joints
 - 10.1.3.5. Ultrasound Assessment of the Neck
 - 10.1.4. Thoracic Cavity Ultrasound
 - 10.1.4.1. Introduction
 - 10.1.4.2. Thoracic Wall
 - 10.1.4.3. Pulmonary Parenchymal Diseases
 - 10.1.4.4. Diaphragm Diseases
 - 10.1.4.5. Mediastinal Diseases

- 10.1.5. Fistulous Tracts and Ultrasound of Masses of Unknown Origin
- 10.2. Computerised Axial Tomography
 - 10.2.1. Introduction
 - 10.2.2. CT Equipment
 - 10.2.3. Nomenclature Hounsfield Units
 - 10.2.4. Diagnosis in Neurology
 - 10.2.4.1. Head
 - 10.2.4.2. Nasal Cavity and Cranial Cavity
 - 10.2.4.3. Spinal Column Myelo CT
 - 10.2.5. Orthopedic Diagnosis
 - 10.2.5.1. Skeletal System
 - 10.2.5.2. Joint Diseases
 - 10.2.5.3. Developmental Disorders
 - 10.2.6. Oncology
 - 10.2.6.1. Masses Assessment
 - 10.2.6.2. Pulmonary Metastases
 - 10.2.6.3. Lymphatic System Assessment
 - 10.2.7. Abdominal Diagnosis
 - 10.2.7.1. Abdominal Cavity
 - 10.2.7.2. Urinary System
 - 10.2.7.3. Pancreas
 - 10.2.7.4. Vascularization
 - 10.2.8. Thoracic Diagnosis
 - 10.2.8.1. Lung and Respiratory Tract
 - 10.2.8.2. Thoracic Wall
 - 10.2.8.3. Pleural Space
 - 10.2.8.4. Mediastinum, Heart and Great Vessels
- 10.3. Nuclear Magnetic Resonance Imaging
 - 10.3.1. Introduction
 - 10.3.2. Advantages Inconveniences
 - 10.3.3. Nuclear Magnetic Resonance Imaging Equipment Interpretation Principles
 - 10.3.4. Diagnosis in Neurology
 - 10.3.4.1. Central Nervous System
 - 10.3.4.2. Peripheral Nervous System
 - 10.3.4.3. Spinal Column
 - 10.3.5. Orthopedic Diagnosis
 - 10.3.5.1. Developmental Disorders
 - 10.3.5.2. Joint Diseases
 - 10.3.5.3. Bone Infections and Neoplasms
 - 10.3.6. Oncology
 - 10.3.6.1. Abdominal Masses
 - 10.3.6.2. Lymphonodes
 - 10.3.6.3. Vascularization
 - 10.3.7. Abdominal Diagnosis
 - 10.3.7.1. Abdominal Cavity
 - 10.3.7.2. Main Pathologies
- 10.4. Diagnosis by Minimally Invasive and Interventional Techniques
 - 10.4.1. Endoscopy
 - 10.4.1.1. Introduction
 - 10.4.1.2. Equipment
 - 10.4.1.3. Patient Preparation
 - 10.4.1.4. Examination Routine
 - 10.4.1.5. Identifiable Pathologies
 - 10.4.2. Arthroscopy
 - 10.4.2.1. Introduction
 - 10.4.2.2. Patient Preparation
 - 10.4.2.3. Identifiable Pathologies
 - 10.4.3. Laparoscopy
 - 10.4.3.1. Introduction
 - 10.4.3.2. Patient Preparation
 - 10.4.3.3. Identifiable Pathologies
 - 10.4.4. Catheterization
 - 10.4.4.1. Introduction
 - 10.4.4.2. Technique and Equipment
 - 10.4.4.3. Diagnostic Uses

- 10.5. Radiographic Examination of Exotic Animals
 - 10.5.1. Positioning and Projections
 - 10.5.1.1. Birds
 - 10.5.1.2. Small Mammals
 - 10.5.1.3. Reptiles
- 10.6. Radiographic Pathological Findings of the Skull and Axial Skeleton in Exotic Animals
 - 10.6.1. Radiographic Pathological Findings of the Skull
 - 10.6.1.1. Birds
 - 10.6.1.2. Small Mammals
 - 10.6.1.3. Reptiles
 - 10.6.2. Pathological Findings of the Axial Skeleton
 - 10.6.2.1. Birds
 - 10.6.2.2. Small Mammals
 - 10.6.2.3. Reptiles
- 10.7. Radiographic Pathological Findings of the Thorax in Exotic Animals:
 - 10.7.1. Birds
 - 10.7.1.1. Nasal Passages and Sinuses
 - 10.7.1.2. Trachea and Syrinx
 - 10.7.1.3. Lungs
 - 10.7.1.4. Air Sacs
 - 10.7.1.5. Heart and Blood Vessels
 - 10.7.2. Small Mammals
 - 10.7.2.1. Pleural Cavity
 - 10.7.2.2. Trachea
 - 10.7.2.3. Oesophageal
 - 10.7.2.4. Lungs
 - 10.7.2.5. Heart and Blood Vessels
 - 10.7.3. Reptiles
 - 10.7.3.1. Respiratory Tract
 - 10.7.3.2. Heart
- 10.8. Radiographic Pathological Findings of the Abdomen in Exotic Animals:
 - 10.8.1. Birds
 - 10.8.1.1. Proventricle, Ventricle and Intestine
 - 10.8.1.2. Liver, Gallbladder and Spleen
 - 10.8.1.3. Urogenital Tract
 - 10.8.2. Small Mammals
 - 10.8.2.1. Stomach, Appendix, Small and Large Intestines
 - 10.8.2.2. Pancreas, Liver and Spleen
 - 10.8.2.3. Urogenital Tract
 - 10.8.3. Reptiles
 - 10.8.3.1. Gastrointestinal Tract and Liver
 - 10.8.3.2. Urinary Tract
 - 10.8.3.3. Genital Tract
- 10.9. Radiographic Pathological Findings in Fore and Hind Limbs in Exotic Animals
 - 10.9.1. Forelimbs
 - 10.9.1.1. Birds
 - 10.9.1.2. Small Mammals
 - 10.9.1.3. Reptiles
 - 10.9.2. Hind Limbs
 - 10.9.2.1. Birds
 - 10.9.2.2. Small Mammals
 - 10.9.2.3. Reptiles
- 10.10. Other Diagnostic Processes in Exotic Animals
 - 10.10.1. Ultrasound
 - 10.10.1.1. Birds
 - 10.10.1.2. Small Mammals
 - 10.10.1.3. Reptiles
 - 10.10.2. Computed Tomography (CT)
 - 10.10.2.1. Birds
 - 10.10.2.2. Small Animals
 - 10.10.2.3. Reptiles
 - 10.10.3. Magnetic Resonance Imaging (MRI)
 - 10.10.3.1. Birds
 - 10.10.3.2. Small Animals
 - 10.10.3.3. Reptiles

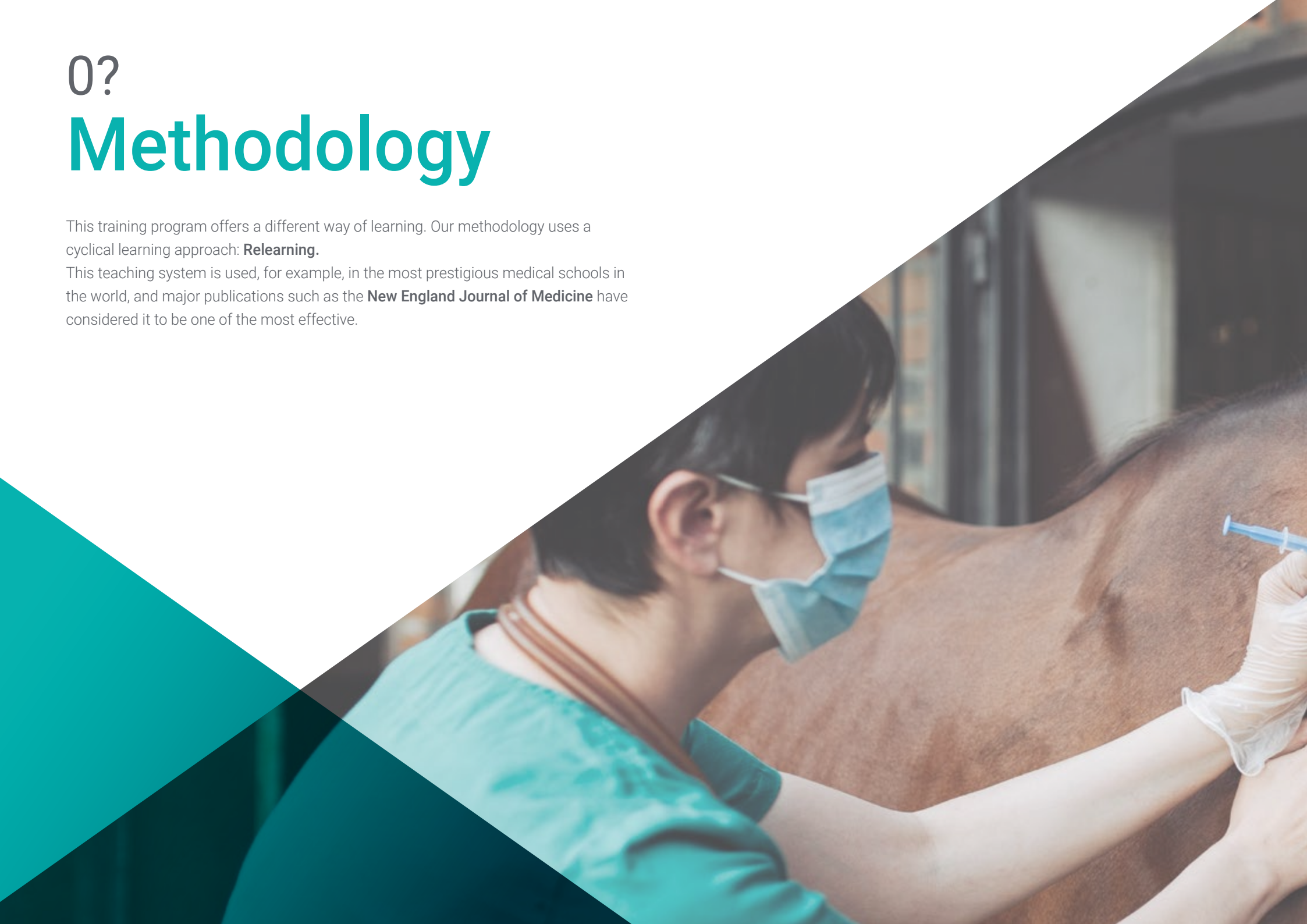

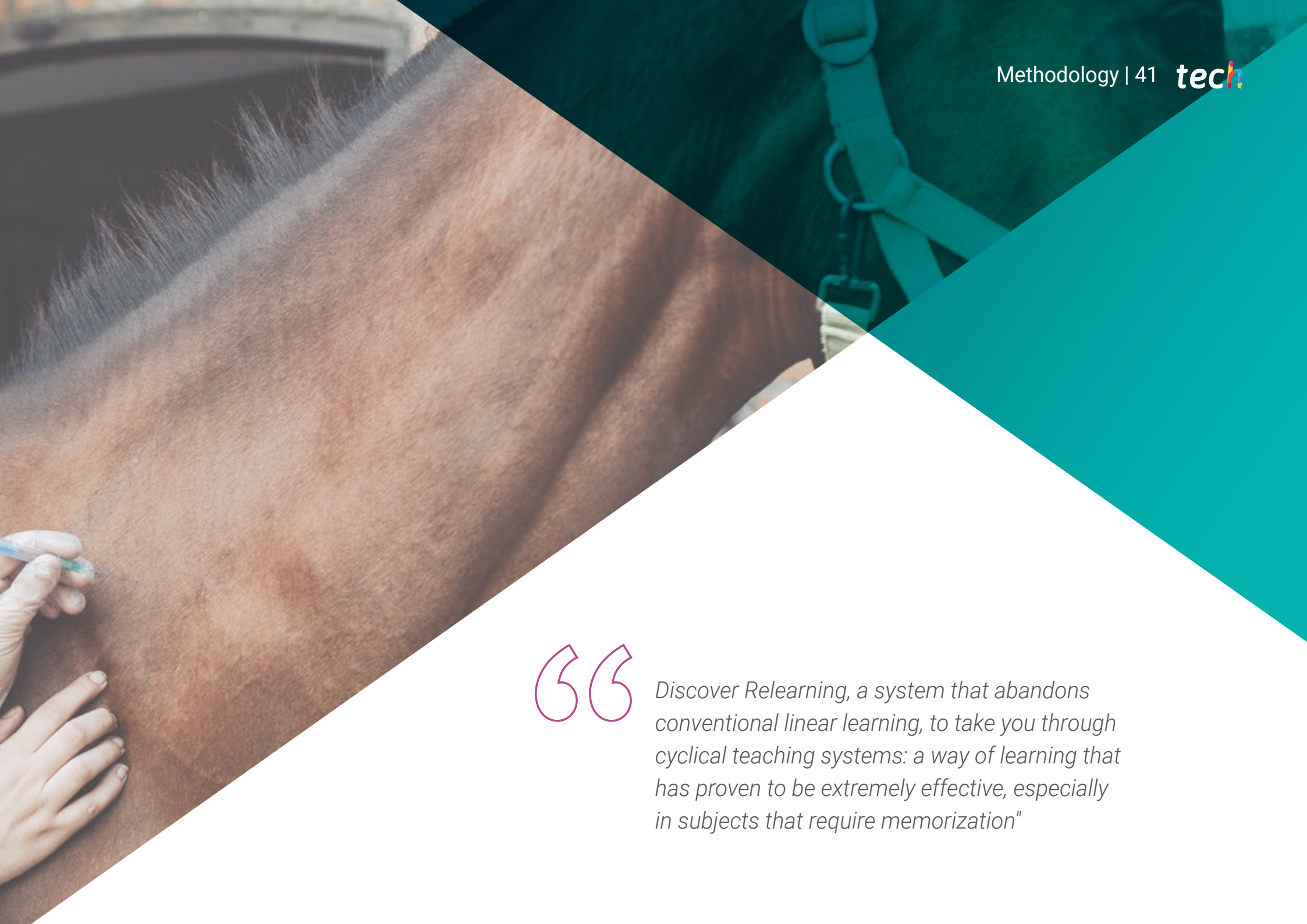0?

Methodology

This training program offers a different way of learning. Our methodology uses a cyclical learning approach: **Relearning**.

This teaching system is used, for example, in the most prestigious medical schools in the world, and major publications such as the **New England Journal of Medicine** have considered it to be one of the most effective.





“

Discover Relearning, a system that abandons conventional linear learning, to take you through cyclical teaching systems: a way of learning that has proven to be extremely effective, especially in subjects that require memorization"

At TECH we use the Case Method

What should a professional do in a given situation? Throughout the program you will be presented with multiple simulated clinical cases based on real patients, where you will have to investigate, establish hypotheses and, finally, resolve the situation. There is an abundance of scientific evidence on the effectiveness of the method. Specialists learn better, faster, and more sustainably over time.

With TECH you will experience a way of learning that is shaking the foundations of traditional universities around the world.



According to Dr. Gervas, the clinical case is the annotated presentation of a patient, or group of patients, which becomes a "case", an example or model that illustrates some peculiar clinical component, either because of its teaching power or because of its uniqueness or rarity. It is essential that the case is based on current professional life, in an attempt to recreate the actual conditions in a veterinarian's professional practice.

“

Did you know that this method was developed in 1912, at Harvard, for law students? The case method consisted of presenting students with real-life, complex situations for them to make decisions and justify their decisions on how to solve them. In 1924, Harvard adopted it as a standard teaching method.

The effectiveness of the method is justified by four fundamental achievements:

1. Veterinarians who follow this method not only manage to assimilate concepts, but also develop their mental capacity through exercises to evaluate real situations and knowledge application.
2. Learning is solidly translated into practical skills that allow the student to better integrate into the real world.
3. Ideas and concepts are understood more efficiently, given that the example situations are based on real-life.
4. The feeling that the effort invested is effective becomes a very important motivation for veterinarians, which translates into a greater interest in learning and an increase in the time dedicated to working on the course.

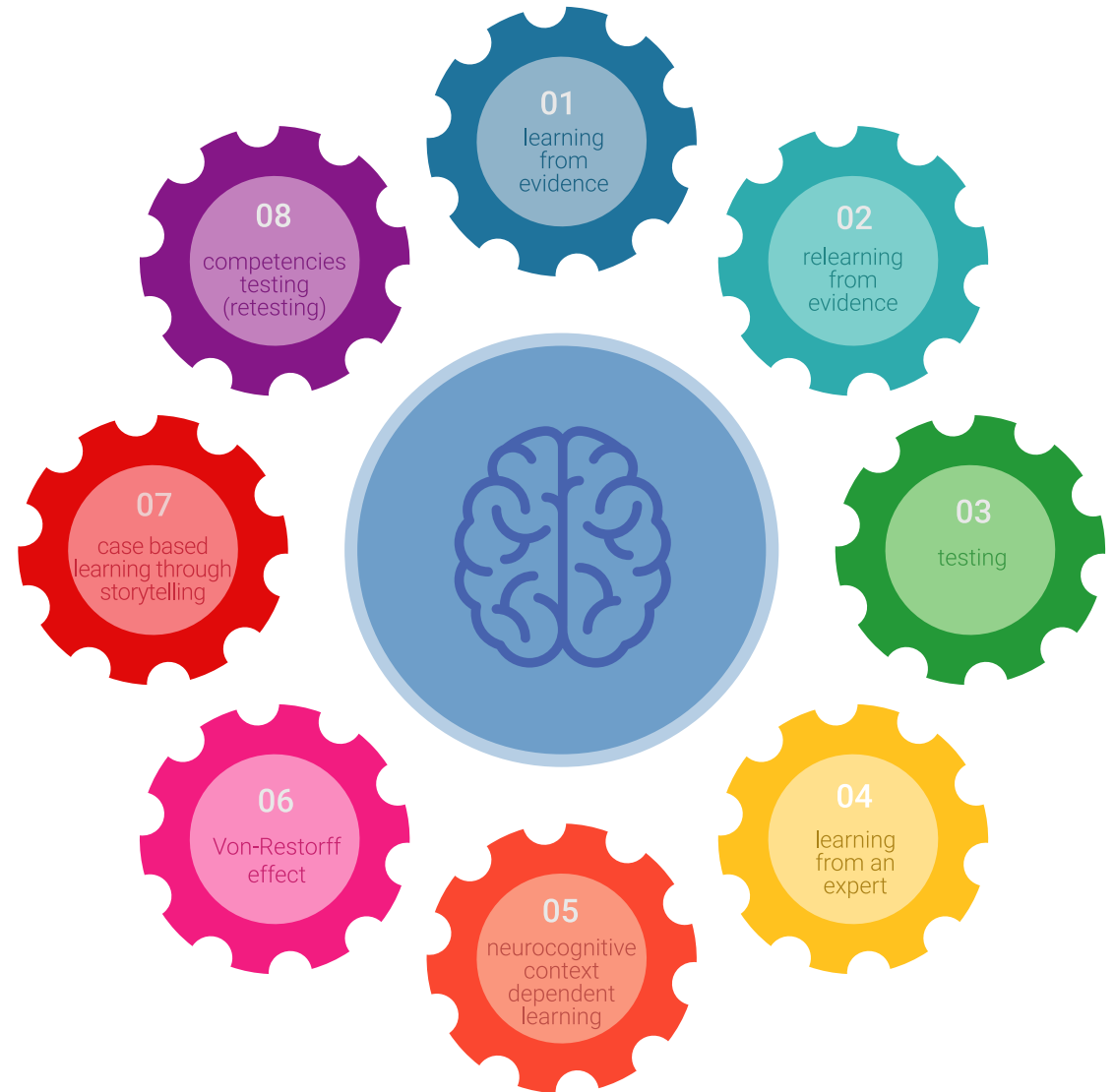

Relearning Methodology

At TECH we enhance the Harvard case method with the best 100% online teaching methodology available: Relearning.

This university is the first in the world to combine the study of clinical cases with a 100% online learning system based on repetition, combining a minimum of 8 different elements in each lesson, a real revolution with respect to the mere study and analysis of cases.

Veterinarians will learn through real cases and by resolving complex situations in simulated learning environments. These simulations are developed using state-of-the-art software to facilitate immersive learning.



At the forefront of world teaching, the Relearning method has managed to improve the overall satisfaction levels of professionals who complete their studies, with respect to the quality indicators of the best online university (Columbia University).

With this methodology more than 65,000 veterinarians have been trained with unprecedented success in all clinical specialties, regardless of the surgical load. Our teaching method is developed in a highly demanding environment, where the students have a high socio-economic profile and an average age of 43.5 years.

Relearning will allow you to learn with less effort and better performance, involving you more in your training, developing a critical mindset, defending arguments, and contrasting opinions: a direct equation for success.

In our program, learning is not a linear process, but rather a spiral (learn, unlearn, forget, and re-learn). Therefore, we combine each of these elements concentrically.

The overall score obtained by TECH's learning system is 8.01, according to the highest international standards.



This program offers the best educational material, prepared with professionals in mind:



Study Material

All teaching material is produced by the specialists who teach the course, specifically for the course, so that the teaching content is highly specific and precise.

These contents are then applied to the audiovisual format, to create the TECH online working method. All this, with the latest techniques that offer high quality pieces in each and every one of the materials that are made available to the student.



Latest Techniques and Procedures on Video

TECH introduces students to the latest techniques, the latest educational advances and to the forefront of current and procedures of veterinary techniques. All of this in direct contact with students and explained in detail so as to aid their assimilation and understanding. And best of all, you can watch the videos as many times as you like.



Interactive Summaries

The TECH team presents the contents attractively and dynamically in multimedia lessons that include audio, videos, images, diagrams, and concept maps in order to reinforce knowledge.

This exclusive multimedia content presentation training Exclusive system was awarded by Microsoft as a "European Success Story".



Additional Reading

Recent articles, consensus documents and international guidelines, among others. In TECH's virtual library, students will have access to everything they need to complete their course.





Expert-Led Case Studies and Case Analysis

Effective learning ought to be contextual. Therefore, TECH presents real cases in which the expert will guide students, focusing on and solving the different situations: a clear and direct way to achieve the highest degree of understanding.



Testing & Retesting

We periodically evaluate and re-evaluate students' knowledge throughout the program, through assessment and self-assessment activities and exercises: so that they can see how they are achieving your goals.



Classes

There is scientific evidence suggesting that observing third-party experts can be useful.

Learning from an Expert strengthens knowledge and memory, and generates confidence in future difficult decisions.



Quick Action Guides

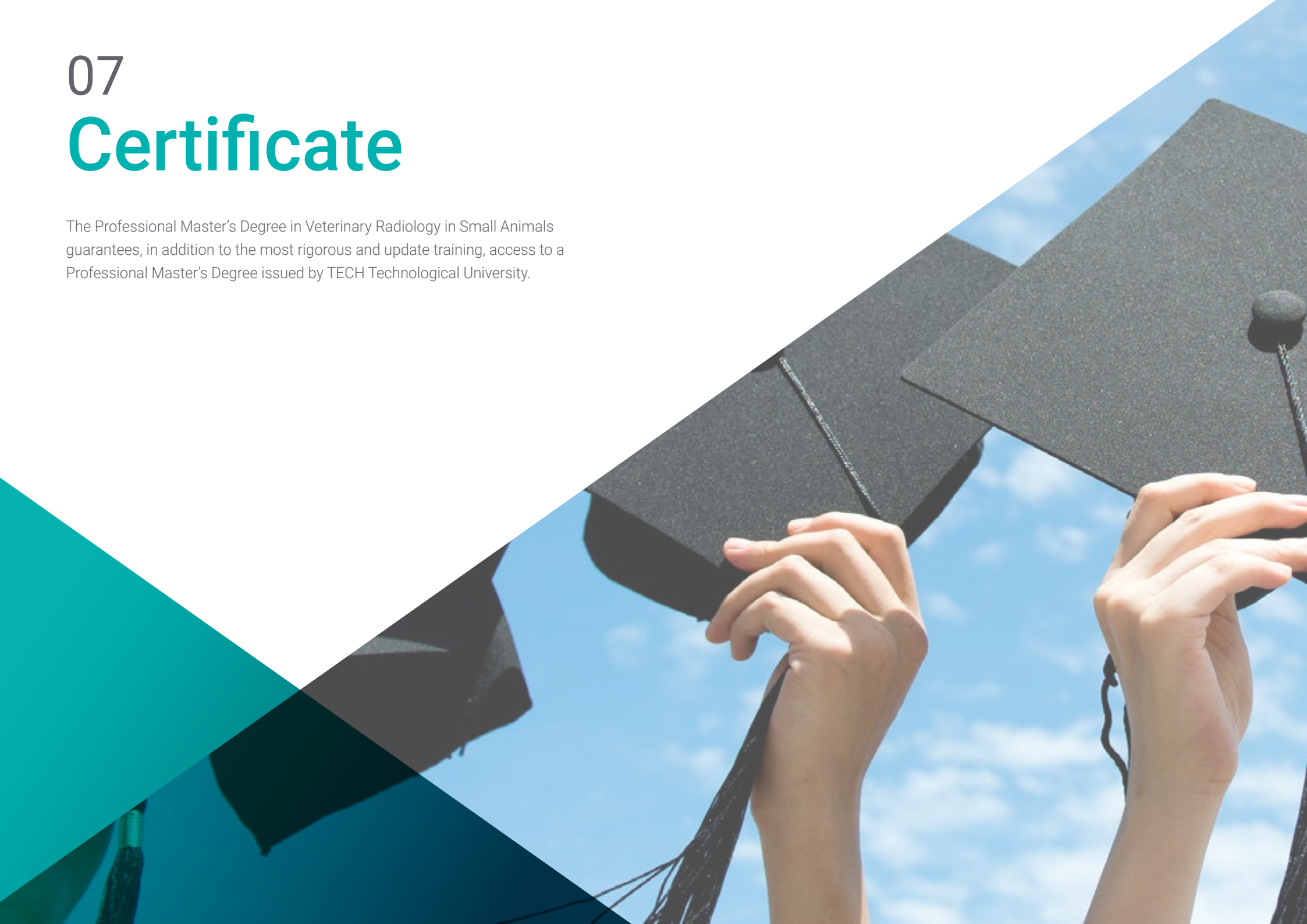TECH offers the most relevant contents of the course in the form of worksheets or quick action guides. A synthetic, practical, and effective way to help students progress in their learning.



07

Certificate

The Professional Master's Degree in Veterinary Radiology in Small Animals guarantees, in addition to the most rigorous and update training, access to a Professional Master's Degree issued by TECH Technological University.



“

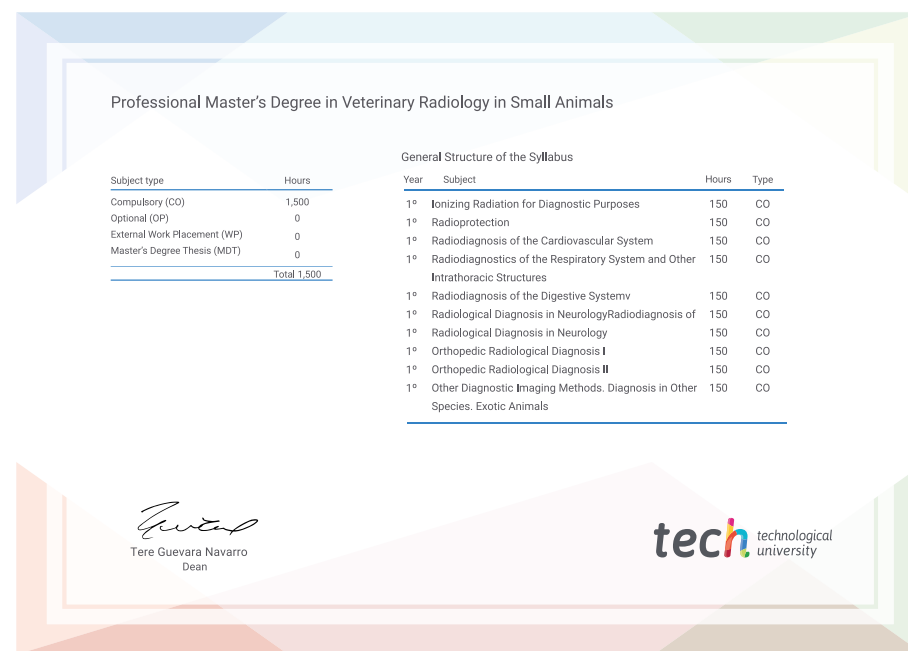
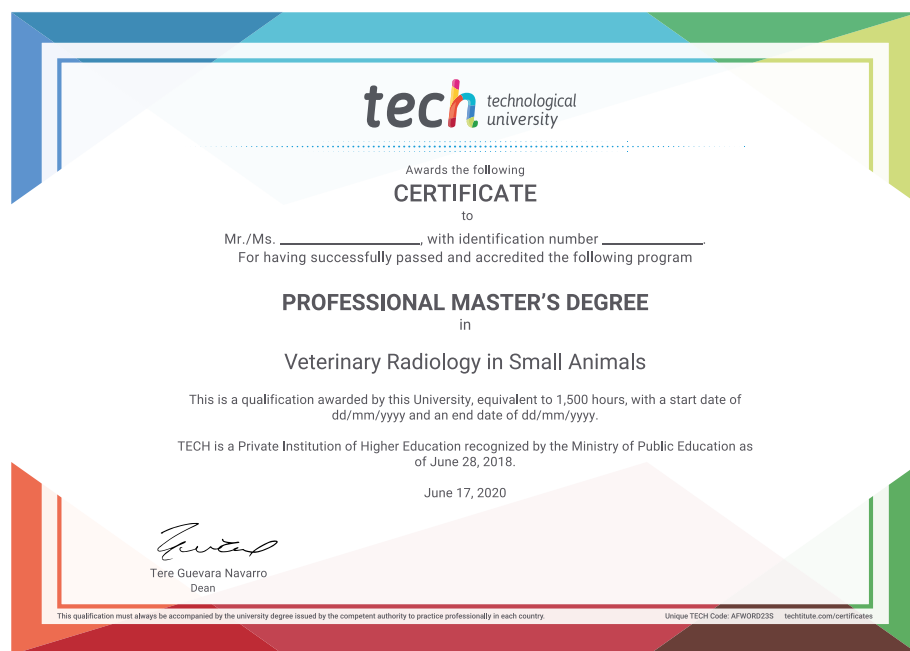Successfully complete this training and receive your university degree without travel or laborious paperwork”

This **Professional Master's Degree in Veterinary Radiology in Small Animals** contains the scientific most complete and update program on the market.

After you have passed the evaluations, you will receive your corresponding by **Professional Master's Degree** issued by **TECH Technological University** via tracked delivery*.

The certificate issued by **TECH Technological University** will reflect the qualification obtained in the Professional Master's Degree, and meets the requirements commonly demanded by labor exchanges, competitive examinations, and professional from career evaluation committees.

Title: **Professional Master's Degree in Veterinary Radiology in Small Animals**
 Official N° of hours: **1,500 h.**



*Apostille Convention. In the event that the student wishes to have their paper certificate issued with an apostille, TECH EDUCATION will make the necessary arrangements to obtain it, at an additional cost.

future
health confidence people
education information tutors
guarantee accreditation teaching
institutions technology learning
community commitment
personalized service innovation
knowledge present quality
online training
development language
classroom



Professional Master's Degree

Veterinary Radiology
in Small Animals

- » Modality: online
- » Duration: 12 months
- » Certificate: TECH Technological University
- » Dedication: 16h/week
- » Schedule: at your own pace
- » Exams: online

Professional Master's Degree

Veterinary Radiology in Small Animals

