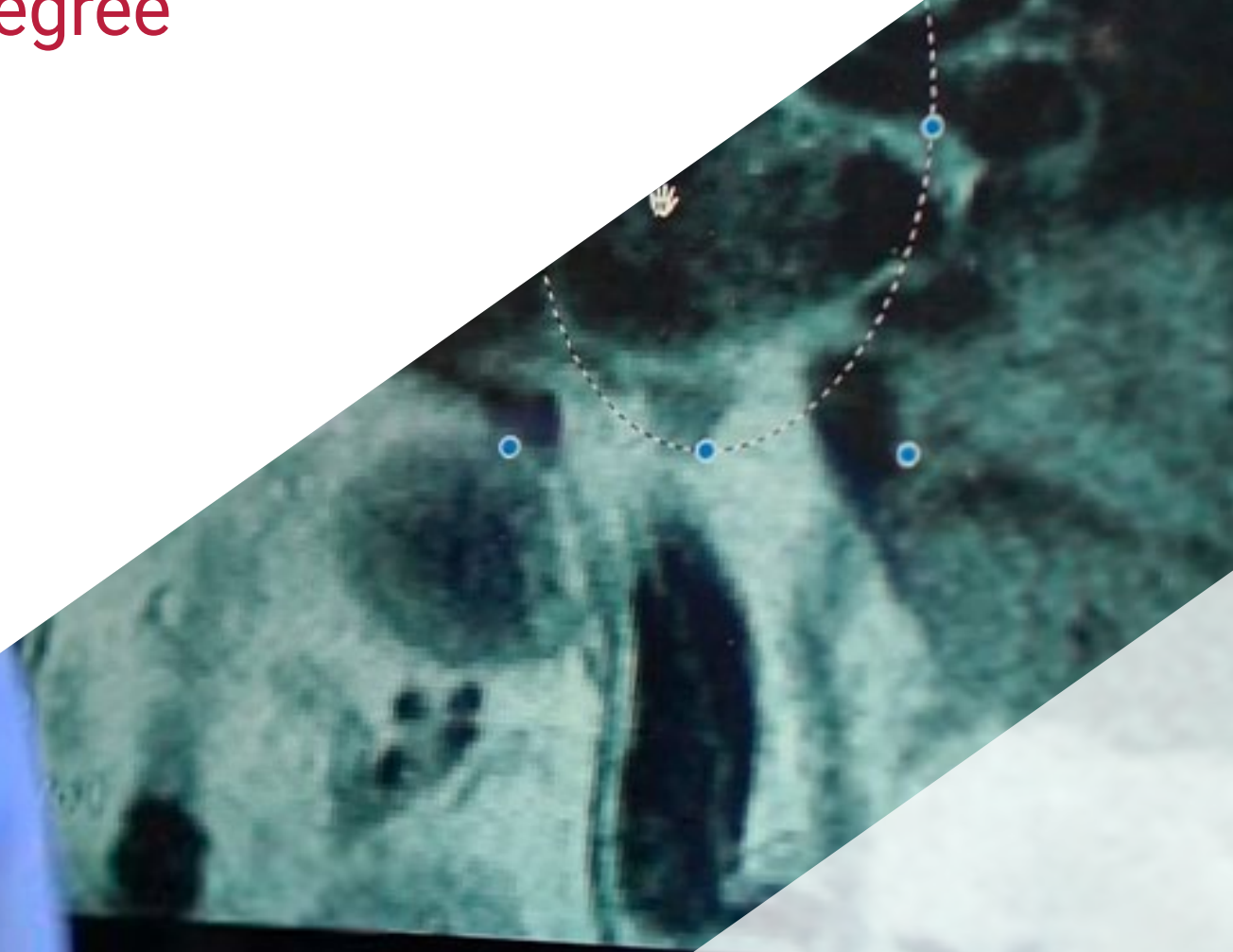


Professional Master's Degree

Forensic Radiology





Professional Master's Degree Forensic Radiology

- » Modality: online
- » Duration: 12 months
- » Certificate: TECH Global University
- » Credits: 60 ECTS
- » Schedule: at your own pace
- » Exams: online

Website: www.techtitute.com/us/medicine/professional-master-degree/master-forensic-radiology

Index

01

Introduction

p. 4

02

Objectives

p. 8

03

Skills

p. 16

04

Course Management

p. 20

05

Structure and Content

p. 24

06

Methodology

p. 36

07

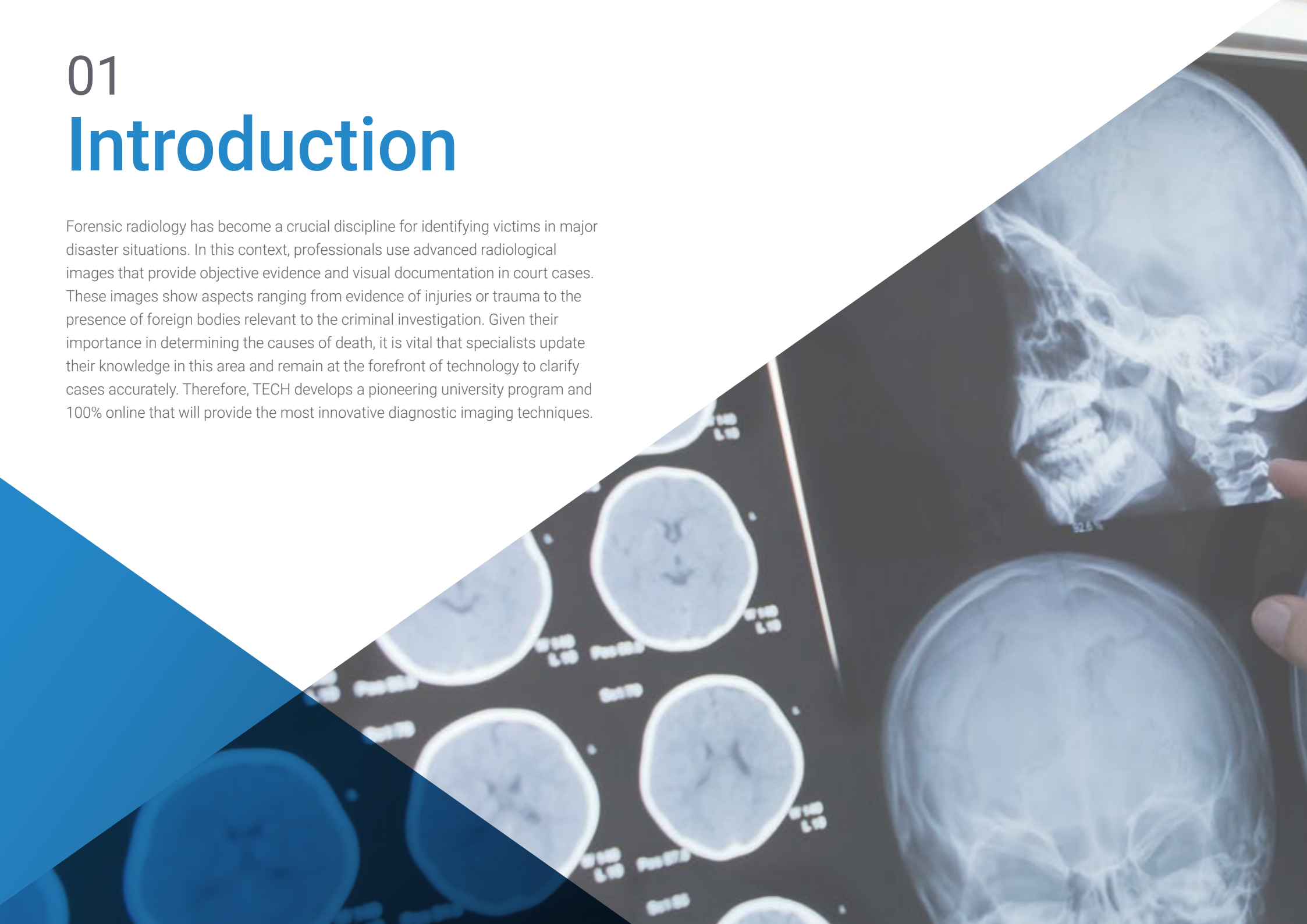Certificate

p. 44

01

Introduction

Forensic radiology has become a crucial discipline for identifying victims in major disaster situations. In this context, professionals use advanced radiological images that provide objective evidence and visual documentation in court cases. These images show aspects ranging from evidence of injuries or trauma to the presence of foreign bodies relevant to the criminal investigation. Given their importance in determining the causes of death, it is vital that specialists update their knowledge in this area and remain at the forefront of technology to clarify cases accurately. Therefore, TECH develops a pioneering university program and 100% online that will provide the most innovative diagnostic imaging techniques.



“

Thanks to this 100% online Professional Master's Degree, you will be able to interpret radiological images rigorously and discover findings of utmost importance for forensic investigations"

The advance of technology has had a great impact on Forensic Medicine, allowing practitioners to obtain significant data from sophisticated machinery such as Computed Tomography, Magnetic Resonance Imaging and Ultrasound. In this way, specialists have applied these procedures to autopsies to obtain detailed images of the internal structures of the human body. As a result, experts have been able to quickly detect injuries or abnormalities that have allowed findings to be thoroughly documented for legal purposes. However, these instruments can present a number of challenges due to the variability of clinical and pathological presentations.

Aware of this reality, TECH implements a revolutionary Professional Master's Degree in Forensic Radiology that will allow professionals to overcome the challenges in this area and thus elevate their daily practice to a higher level. To achieve this, the academic itinerary will provide graduates with the keys to effectively handle the main diagnostic imaging tools (among which X-Ray systems, Ultrasound or MRI stand out). Additionally, the academic contents will delve into the skeleton of the human being at different stages of development.

In this way, specialists will have at their disposal the most effective resources for the detection of common traumatic injuries, such as fractures or dislocations. In addition, the program will include several case studies that will bring them closer to the methodologies used in forensic radiographs.

As for the methodology of this university program, it is taught in a convenient 100% online format, adapting to the needs of each student. It is also based on the innovative *Relearning* teaching system, of which TECH is a pioneer. This method consists of the reiteration of key concepts, ensuring that students consolidate their knowledge progressively. All this with the support of a teaching staff of international prestige, which will support you throughout your academic itinerary.

This **Professional Master's Degree in Forensic Radiology** contains the most complete and up-to-date scientific program on the market. The most important features include:

- ♦ The development of practical cases presented by experts in Forensic Radiology
- ♦ The graphic, schematic and eminently practical contents with which it is conceived gather scientific and practical information on those disciplines that are indispensable for professional practice
- ♦ Practical exercises where self-assessment can be used to improve learning
- ♦ Its special emphasis on innovative methodologies
- ♦ Theoretical lessons, questions to the expert, debate forums on controversial topics, and individual reflection assignments
- ♦ Content that is accessible from any fixed or portable device with an Internet connection



You will handle the most sophisticated radiological technology to identify human remains in cases of serious accidents, violent crimes and even natural disasters"

“

Looking to specialize in Firearms and Explosives Trauma Radiology? Get it in as little as 12 months with this university program"

The program's teaching staff includes professionals from the field who contribute their work experience to this educational program, as well as renowned specialists from leading societies and prestigious universities.

The multimedia content, developed with the latest educational technology, will provide the professional with situated and contextual learning, i.e., a simulated environment that will provide immersive education programmed to learn in real situations.

This program is designed around Problem-Based Learning, whereby the professional must try to solve the different professional practice situations that arise during the course. For this purpose, students will be assisted by an innovative interactive video system created by renowned and experienced experts.

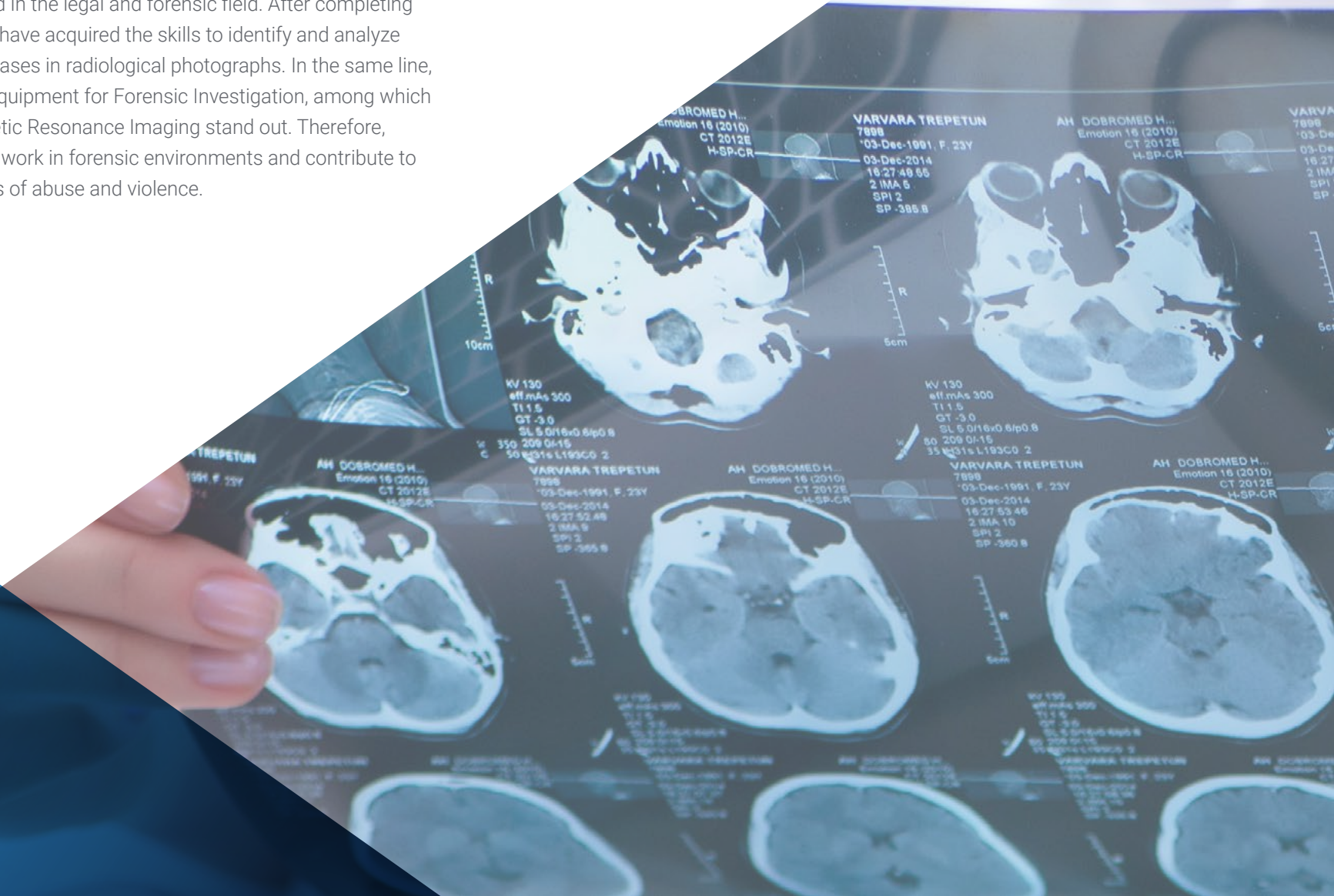You will delve into the use of Radiobiology Equipment to identify victims of radiation injuries.

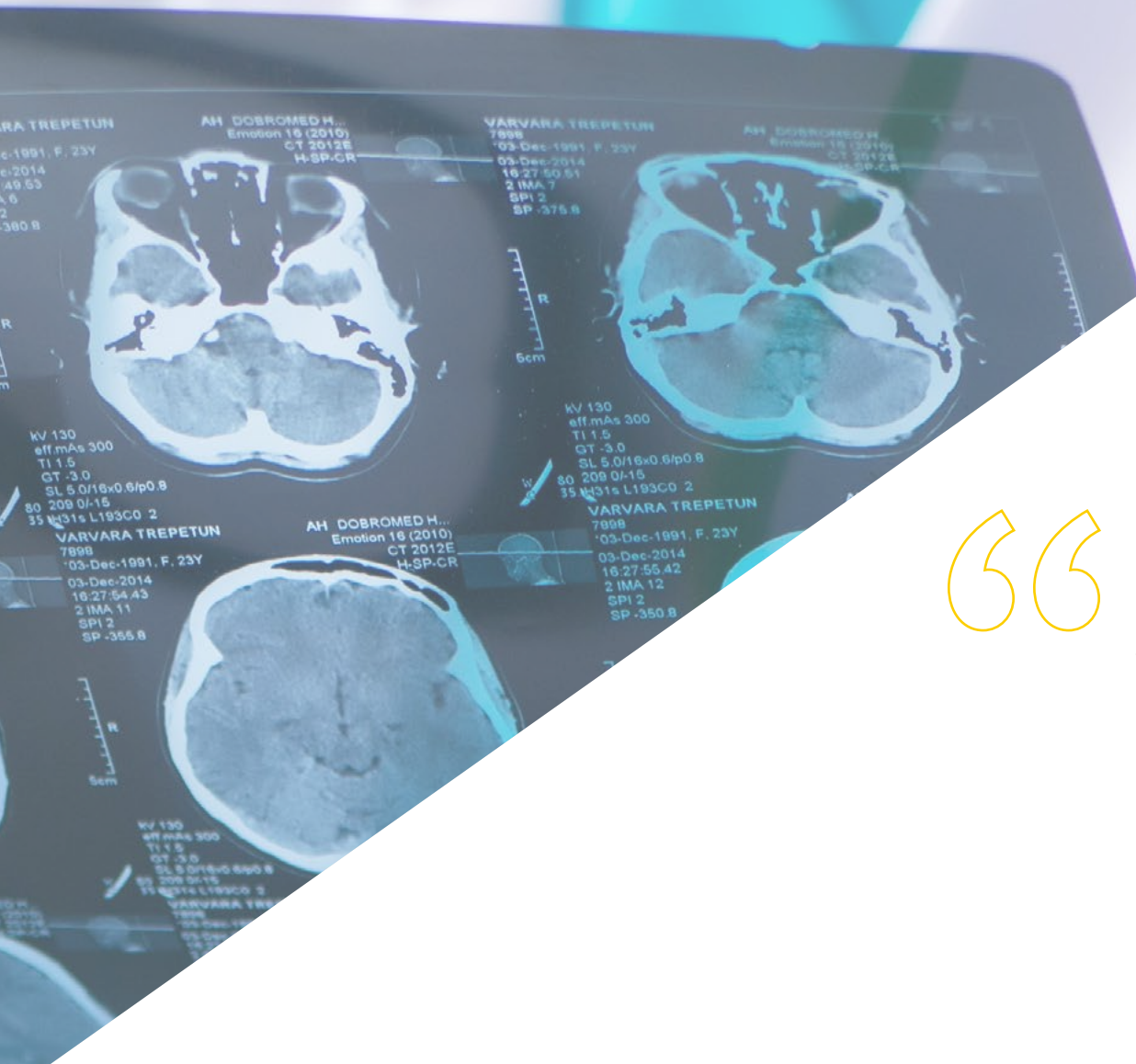With the Relearning methodology, you will update your knowledge from the comfort of your home and without the need to travel to an on-site academic center.



02 Objectives

This Professional Master's Degree will specialize graduates in the different diagnostic imaging techniques used in the legal and forensic field. After completing the university program, experts will have acquired the skills to identify and analyze patterns of injuries, traumas or diseases in radiological photographs. In the same line, professionals will master specific equipment for Forensic Investigation, among which Computed Tomography and Magnetic Resonance Imaging stand out. Therefore, graduates will be highly qualified to work in forensic environments and contribute to aspects such as evaluation in cases of abuse and violence.





“

You will meet your most ambitious career goals thanks to the distinctive approach of this academic pathway. You will become the most prominent Forensic Radiologist in your environment!”



General Objectives

- ♦ Identify and recognize the different types of radiological equipment and understand their uses and importance in the legal and forensic context
- ♦ Determine the adaptation of each technique to each situation, based on the affinity of the technique to the specific legal case
- ♦ Broaden the knowledge in forensic diagnostic medicine, through the extensive follow-up of the elements that compose an investigation
- ♦ Establish the main role of forensic radiology in the final report of the death trajectory and the judicial investigation
- ♦ Properly identify the different bones of the skeletal system, in their composition, form and function, enabling it to detect appropriate conditions or associated trauma and possible consequences for the proper maintenance of vital and locomotor functions of the individual
- ♦ Interpret radiological images of the human body, bone structures in various radiographic projections and imaging modalities, important for differential diagnosis
- ♦ Recognize the main bone diseases and lesions in radiological images, enabling students to recognize radiological signs of common bone diseases such as fractures, osteoarthritis or osteoporosis, as well as bone tumors and metabolic bone diseases
- ♦ Determine the fundamental principles of radiology and medical imaging technology for solid understanding of the physical and technical principles behind the different radiological imaging modalities, how images are generated, the distinctive features of each technique, and their specific clinical applications in the diagnosis and evaluation of the human skeleton
- ♦ Analyze the sequence of ossification, joint development, and the formation of bony structures and the formation of bone structures at different stages of childhood, as well as the factors that influence bone growth, such as genetics, nutrition and chronic diseases
- ♦ Recognize and diagnose congenital anomalies and disorders of bone development in children on radiographs
- ♦ Develop skills to interpret specific images of the above conditions and understand their impact on growth and musculoskeletal function
- ♦ Understand how skeletal growth and mineralization are processes that begin during fetal development and continue at different rates through childhood and adolescence until the third decade of life, when peak bone mass is reached
- ♦ Identify normal features of childhood bone anatomy, as well as signs of traumatic injuries, bone disease and pediatric orthopedic conditions, with emphasis on the importance of exposure to specific imaging techniques for children and the radiologic safety considerations for this group
- ♦ Analyze the different radiographic techniques, as well as their uses
- ♦ Examine each type of radiography for its correct choice depending on each case
- ♦ Define the different anatomical features of relevance to the identification of the individual
- ♦ Identify the nature of biological maturation of the individual based on birth, growth and bone consolidation

- ♦ Evaluate the characterization of the individual based on sexual dimorphism
- ♦ Establish identifying parameters based on height, complexion by activity and markers of ancestry
- ♦ Define the different pathologies and bone traumas in the human skeleton
- ♦ Identify pathologies or injuries in the body of individuals or corpses with ease, allowing them to contribute in investigations either of criminal acts, identification or cases of negligence of health professionals
- ♦ Evaluate the physical and mechanical characterization behind each element to know how it works
- ♦ Recognize the different injury characteristics based on the type of weapon, mechanical application and nature of the tissue
- ♦ Define the extent of injuries to the tissues of the individual
- ♦ Evaluate the difference in injury between weapon, object and cutting structure
- ♦ Recognize, in conjunction with the previous topic, mixed injury patterns, such as those caused by short-concussive elements
- ♦ Support the application of radiodiagnostic techniques in individuals in order to know the extent of the injuries and in deceased persons from whom no information can be obtained without altering the organic tissue
- ♦ Provide support to other disciplines to characterize the injuries of the individual.
- ♦ Identify and recognize the different types of maxillofacial trauma and the different dental alveolar trauma.
- ♦ Interpret by imaging and know how to differentiate a healthy anatomical structure from an anatomical structure injured by trauma



You will have at your disposal the most innovative educational resources, with free access to the Virtual Campus 24 hours a day"



Specific Objectives

Module 1. Diagnostic Imaging Techniques and Tools in the Forensic Context

- ♦ Learn the terminology that is used
- ♦ Develop the ability to observe, evaluate, experiment, formulate and verify hypotheses and technical reasoning
- ♦ Determine the importance of conventional radiology for the identification of corpses
- ♦ Establish its application in living individuals

Module 2. Forensic Radiology of the Non-Pathological and Non-Traumatic Human Skeleton

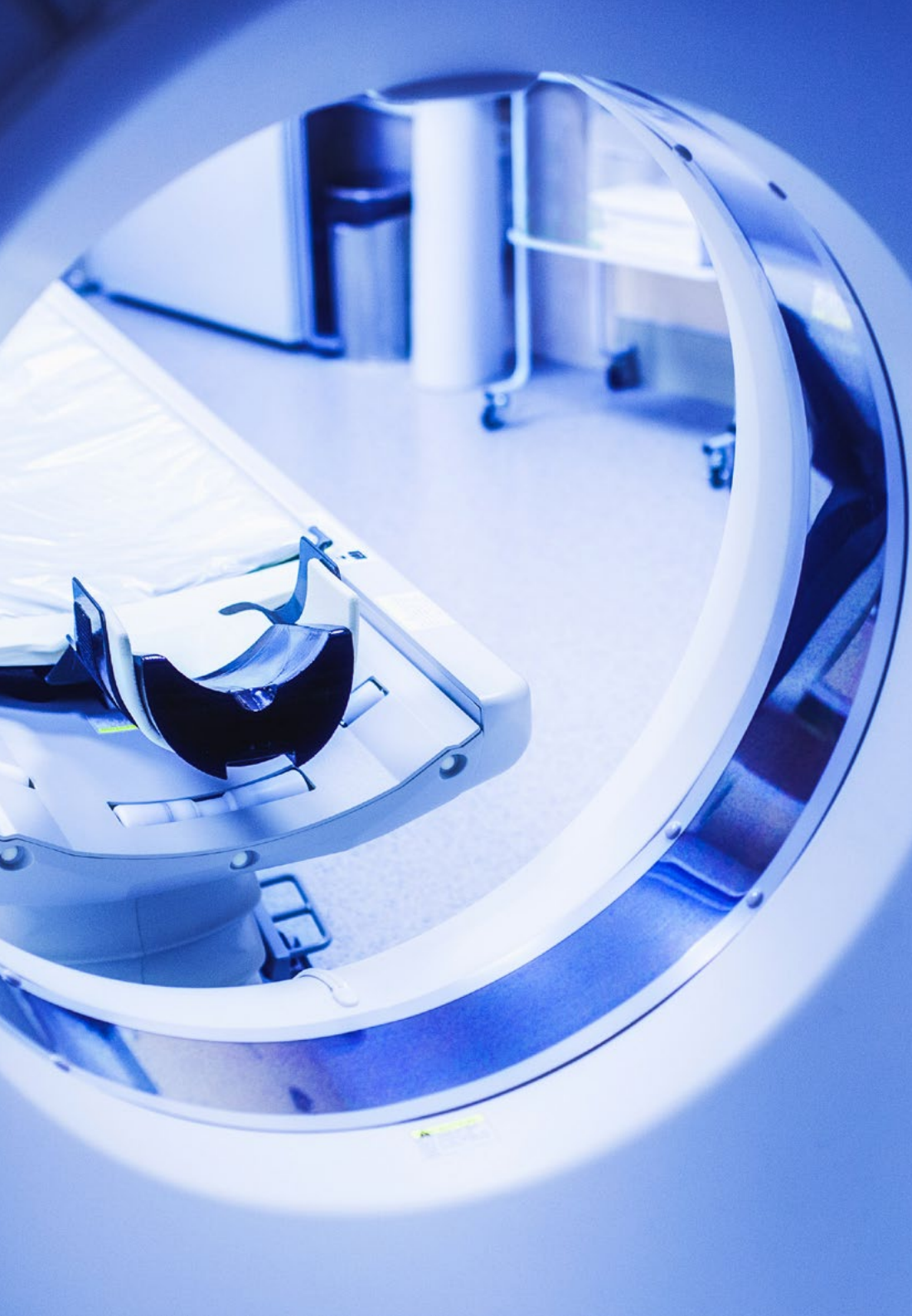- ♦ Contextualize the various anatomical positions, imaging conditions and the specific approach of the most accurate radiological techniques for the analysis of pathology and trauma
- ♦ Examine the most advanced tools in osteological anatomy and osteopathology, illustrated with both multidimensional materials and radiological images
- ♦ Adapt different radiological image analysis techniques to compare bone pathologies and morphoanatomical variations
- ♦ Enable complementation and interdisciplinarity with the knowledge already acquired and the knowledge that will be provided in the following modules

Module 3. Forensic Radiology of the Human Skeleton in Phases of Biological Maturation

- ♦ Determine the development of the bone along the growth phases, from the neonatal phase to adolescence and the respective images obtained by radiographs
- ♦ Master the morphology of healthy bone: its histology, the ossification center, the different types of bone tissues present in the bones and their dynamics during childhood
- ♦ Analyze bone factors with congenital, metabolic and infectious pathologies, distinguishing them from healthy bone and know how to apply the appropriate imaging technique to each case
- ♦ Identify the most frequent bone lesions among children and adolescents, including the establishment of the difference between accidental injuries and injuries possibly resulting from assault and abuse

Module 4. Forensic Maxillofacial Radiology

- ♦ Evaluate the different anatomical and dental structures through imaging
- ♦ Recognize the structures already analyzed in the previous topic through imaging
- ♦ Support the importance of radiodiagnostic techniques in the analysis of the individual's lesion
- ♦ Provide support to other disciplines to characterize the injuries of the individual



Module 5. Forensic Radiology in Human Identification

- ◆ Provide information regarding the biological characterization of the individual based on sex, age, height, ancestry or complexion
- ◆ Adapt the different radiological techniques to living individuals in which information cannot be obtained in any other way
- ◆ Apply radiological techniques to deceased individuals from whom information cannot be obtained without altering the organic tissue or because it is not possible to have access to the interior of the tissue, as in cases of carbonization or in alterations of human decomposition
- ◆ Support other disciplines to characterize the individual in its context

Module 6. Radiodiagnosis of Pathologies Related to Forensic Investigation

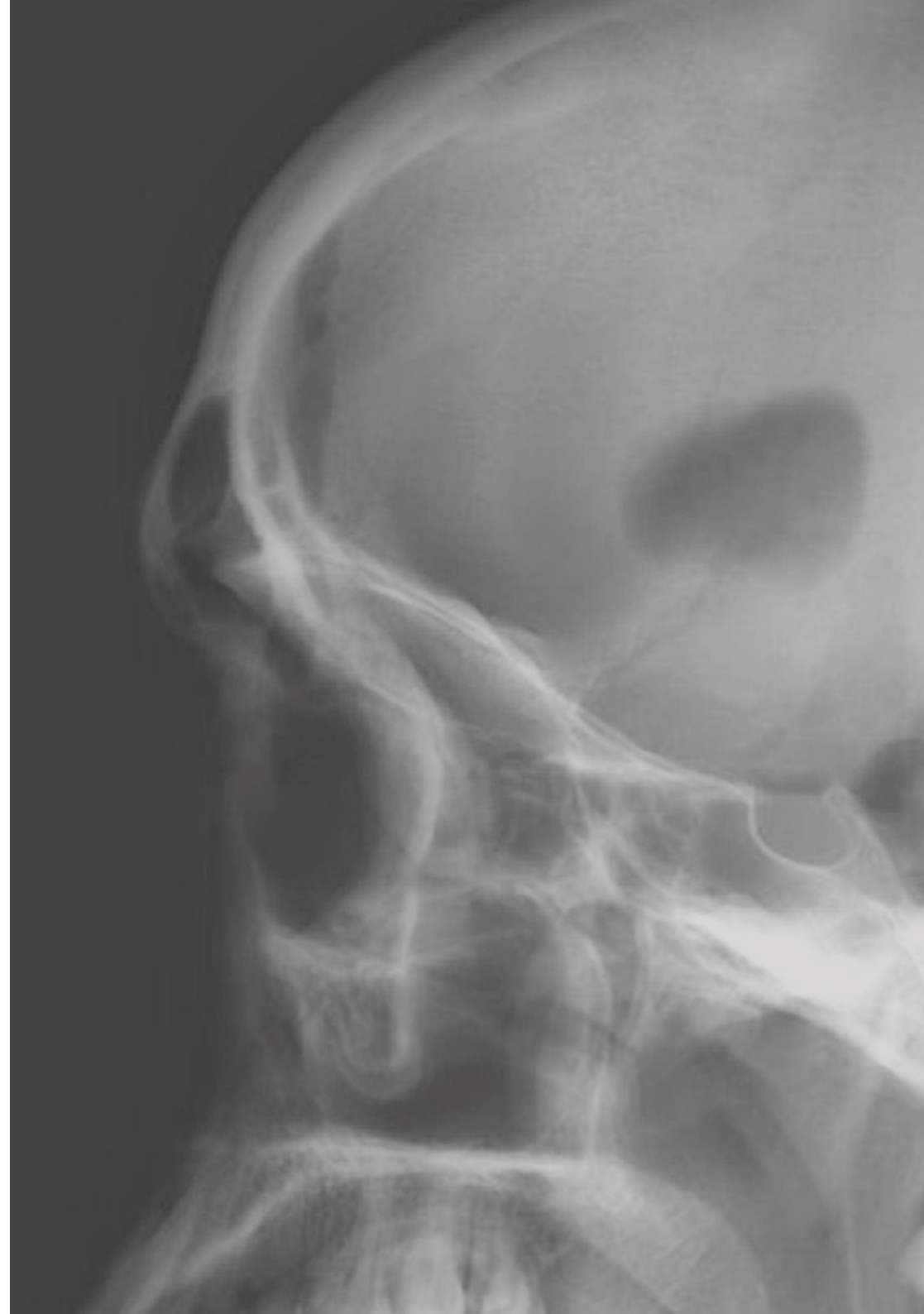
- ◆ Identify the different pathologies through different radiodiagnostic means
- ◆ Help to guide an adequate diagnosis at the time of making an approach or giving an expert opinion
- ◆ Serve as a support technique to individualize and therefore identify an individual.
- ◆ Guide cause and manner of death

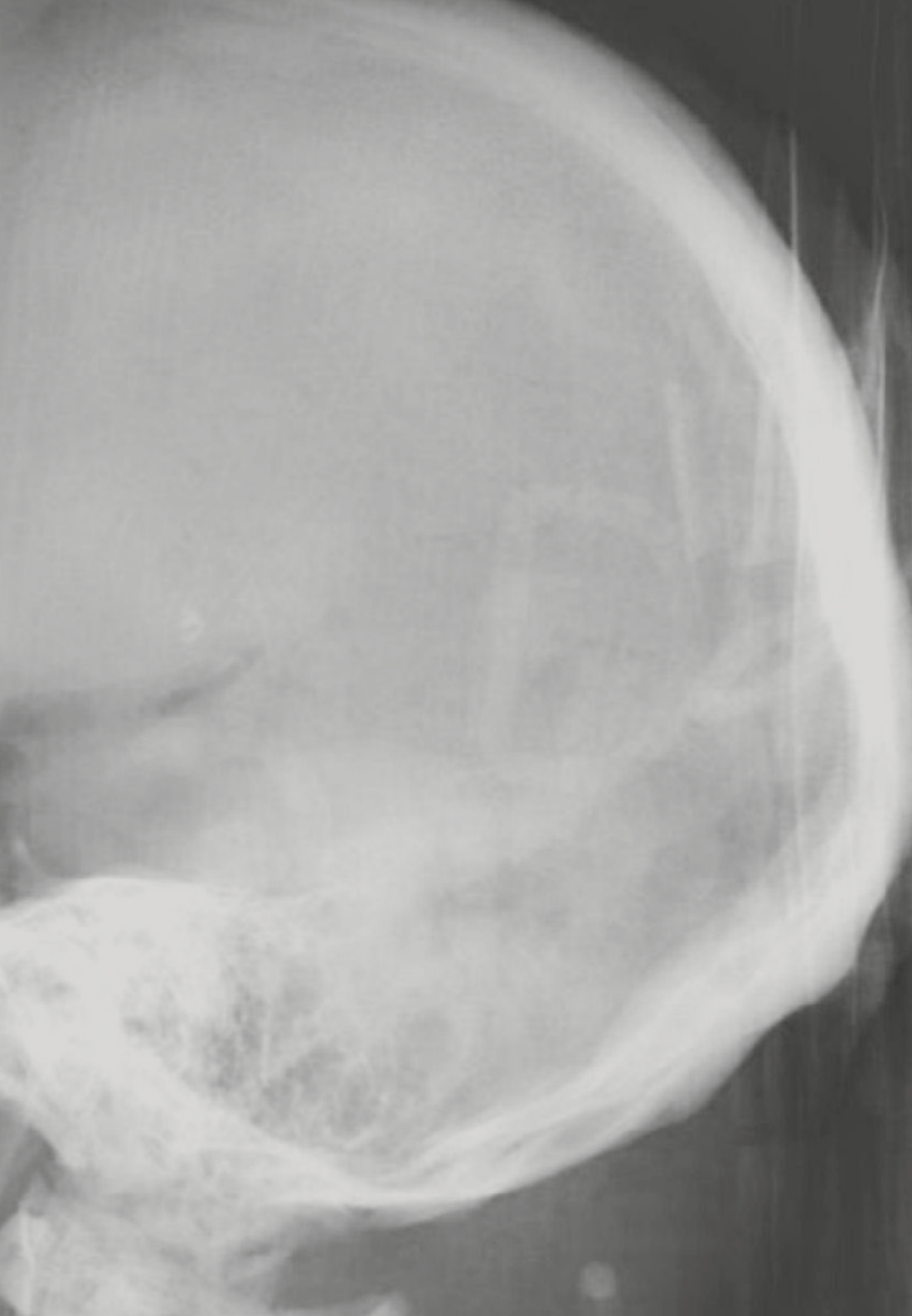
Module 7. Forensic Radiological Techniques of Bone and Dental Trauma with Blunt Objects

- ♦ Identify and recognize the different types of elements that generate blunt injuries in the individual
- ♦ Evaluate the physical and mechanical characterization behind each element to know how it works
- ♦ Recognize the different injury characteristics based on the type of weapon, mechanical application and nature of the tissue
- ♦ Define the extent of injuries to the tissues of the individual

Module 8. Forensic Radiology of Trauma with Sharp and Cutting Elements

- ♦ Evaluate the difference in injury between weapon, object and cutting structure
- ♦ Recognize, in conjunction with the previous topic, mixed injury patterns, such as those caused by short-concussive elements
- ♦ Support the application of radiodiagnostic techniques in individuals in order to know the extent of the injuries and in deceased persons from whom no information can be obtained without altering the organic tissue
- ♦ Provide support to other disciplines to characterize the injuries of the individual





Module 9. Radiology of Firearms and Explosives Trauma in Forensic Investigation

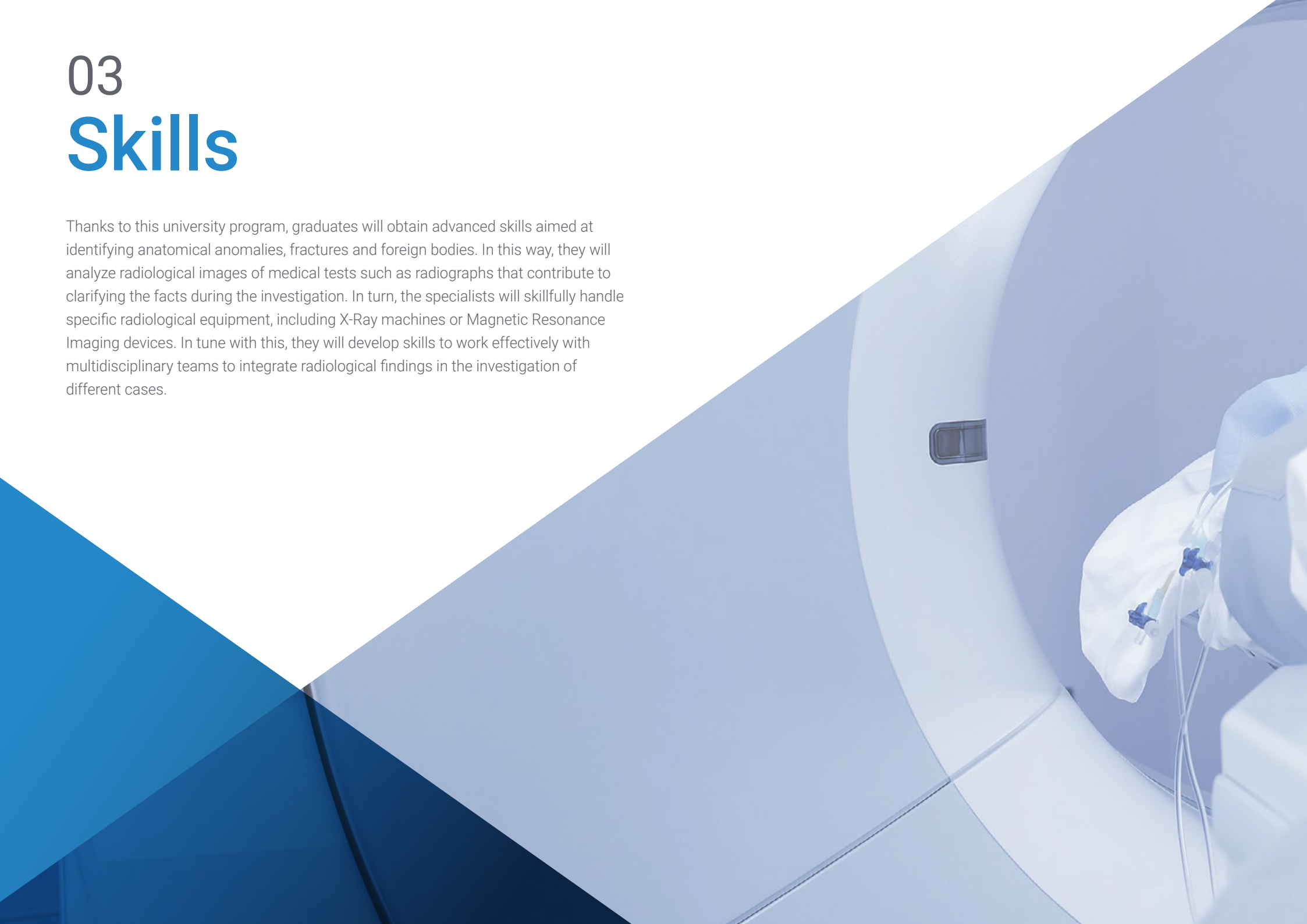- ♦ Identify the different types and patterns of injuries that can be generated by firearm projectiles and explosives
- ♦ Determine the different injuries and systemic compromises that can be generated by firearm projectiles and explosives
- ♦ Identify through radiodiagnostic means injured areas
- ♦ Interpret the role of radiology in the legal world

Module 10. Forensic Radiodiagnosis of Maxillofacial Trauma

- ♦ Evaluate the different injured anatomical and dental structures through imaging
- ♦ Examine the different alveolodental traumas
- ♦ Support the importance of radiodiagnostic techniques in the analysis of the trauma of the individual to be studied
- ♦ Present support to the other disciplines to characterize the individual's trauma

03 Skills

Thanks to this university program, graduates will obtain advanced skills aimed at identifying anatomical anomalies, fractures and foreign bodies. In this way, they will analyze radiological images of medical tests such as radiographs that contribute to clarifying the facts during the investigation. In turn, the specialists will skillfully handle specific radiological equipment, including X-Ray machines or Magnetic Resonance Imaging devices. In tune with this, they will develop skills to work effectively with multidisciplinary teams to integrate radiological findings in the investigation of different cases.



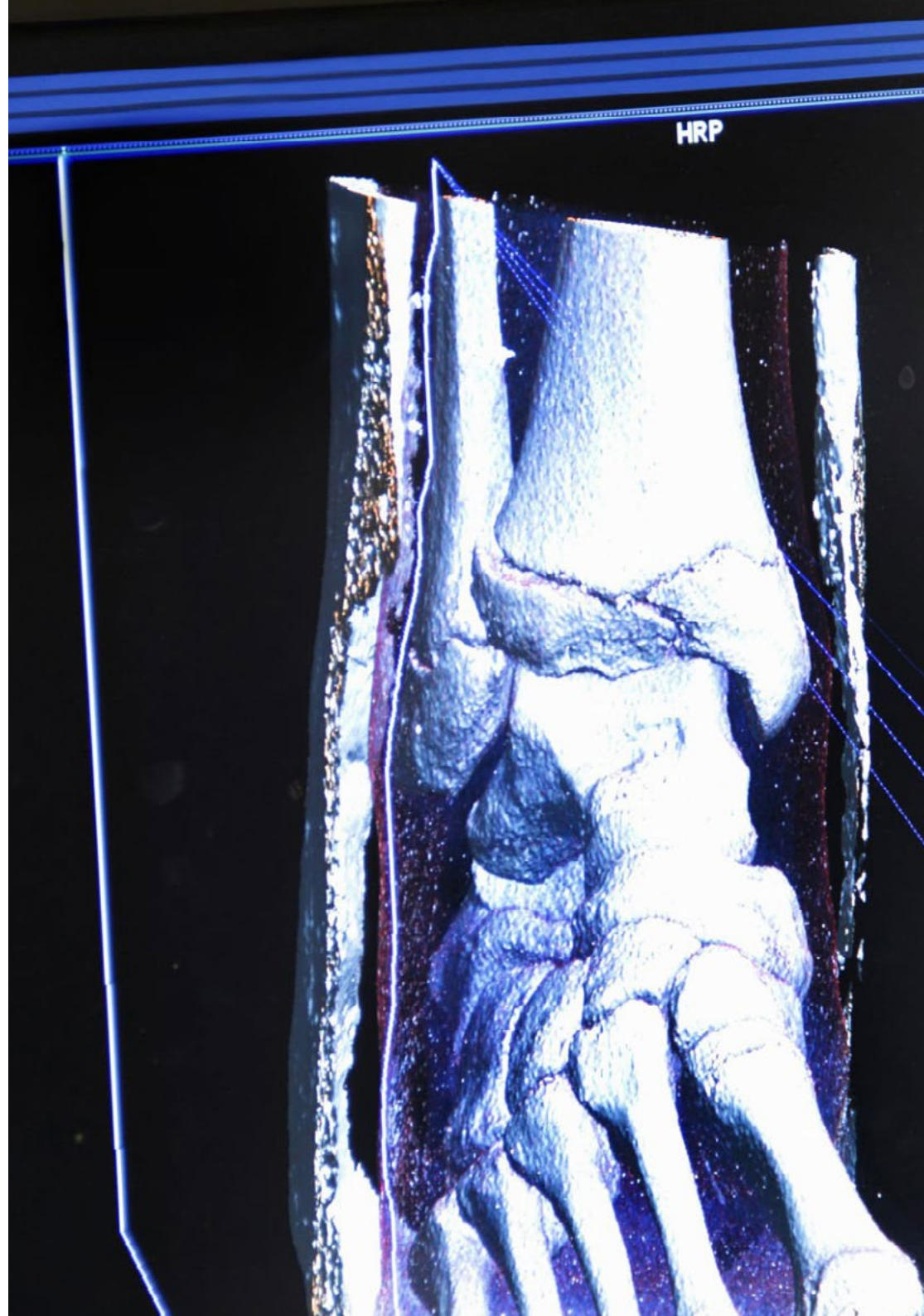“

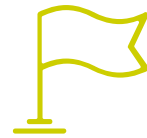You will interpret radiological images in detail to identify lesions, abnormal findings or pathologies and collect them with the circumstances of death"



General Skills

- ◆ Develop a thorough understanding of the basic principles of Radiology, including radiation physics, anatomy and physiology of the human body
- ◆ Utilize specific imaging techniques for forensic investigation, such as Radiography, Computed Tomography and Magnetic Resonance Imaging (MRI)
- ◆ Identify injuries, fractures, wounds and other types of trauma in radiological images, and assess their relevance in the context of a Forensic Investigation
- ◆ Keep abreast of technological and scientific advances in the field of Forensic Radiology





Specific Skills

- Detect specific patterns of injury on radiological images that may be indicative of causes of death, trauma or physical abuse
- Interpret radiological images from autopsies and recognize radiological signs of causes of death, such as internal injuries, bone fractures or presence of foreign objects
- Obtain skills in the proper handling and use of forensic imaging equipment.
- Collaborate effectively with medical examiners, pathologists, criminal investigators and other forensic science experts to integrate radiological findings into the investigation of cases and legal proceedings

“

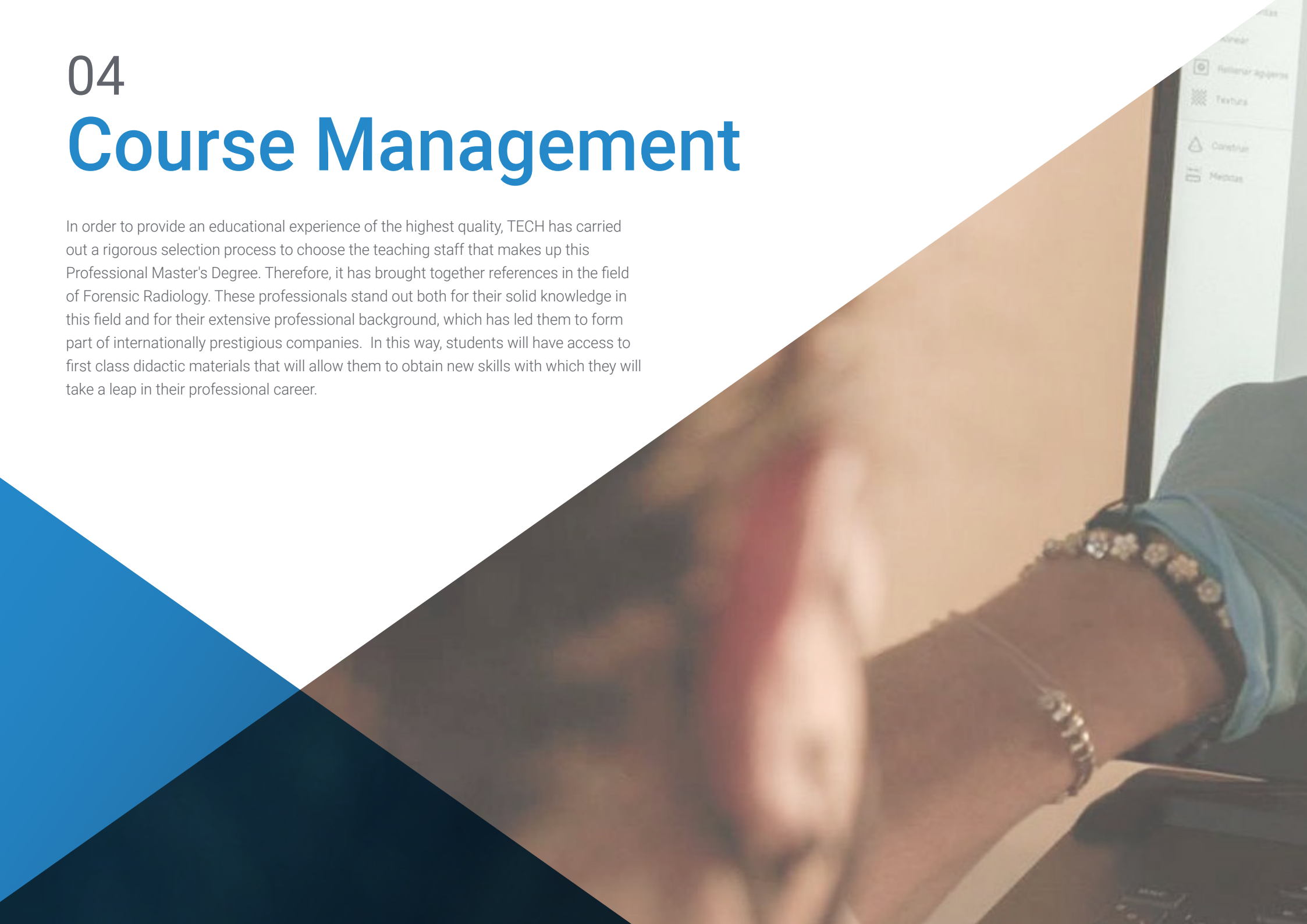You will increase your skills in radiological interpretation of teeth and be able to correctly identify individuals”

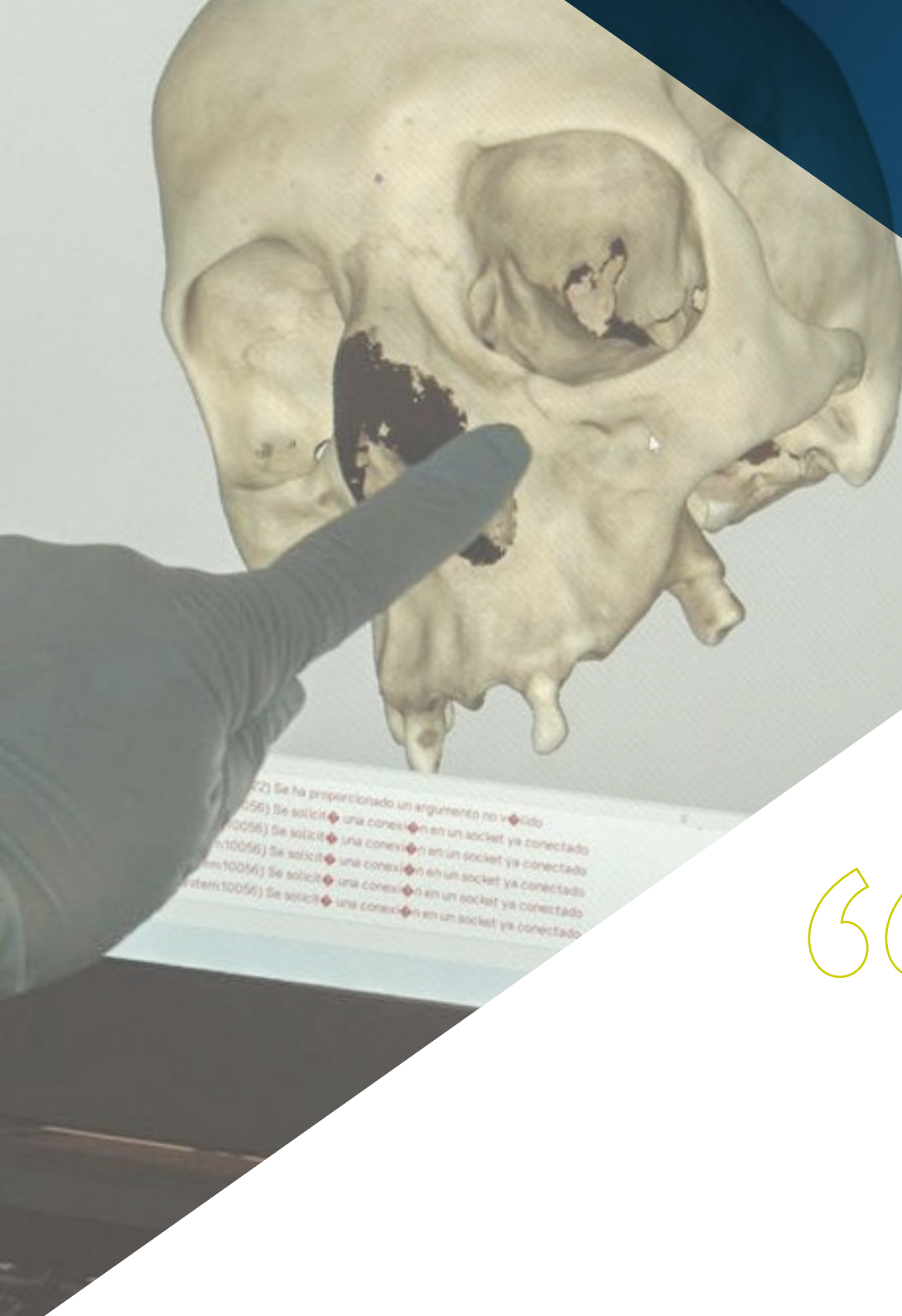

04

Course Management

In order to provide an educational experience of the highest quality, TECH has carried out a rigorous selection process to choose the teaching staff that makes up this Professional Master's Degree. Therefore, it has brought together references in the field of Forensic Radiology. These professionals stand out both for their solid knowledge in this field and for their extensive professional background, which has led them to form part of internationally prestigious companies. In this way, students will have access to first class didactic materials that will allow them to obtain new skills with which they will take a leap in their professional career.





“

You will be able to consult all your doubts directly with the teaching team, receiving personalized tutoring adapted to your own needs”

Management



Dr. Ortega Ruiz, Ricardo

- ♦ Director of the Laboratory of Archeology and Forensic Anthropology of the Institute of Forensic Sciences
- ♦ Investigator of Crimes against Humanity and War Crimes
- ♦ Judicial Expert in Human Identification
- ♦ International Observer in Drug Trafficking Crimes in Iberoamerica
- ♦ Collaborator in police investigations for the search of missing persons in foot or canine tracking with Civil Protection
- ♦ Instructor of adaptation courses in Basic Scale to Executive Scale aimed at the Scientific Police
- ♦ Master's Degree in Forensic Sciences applied to the Search for Missing Persons and Human Identification Cranfield University
- ♦ Master's Degree in Archeology and Heritage with the Specialty of Forensic Archeology for the Search of Missing Persons in Armed Conflict

Professors

Dr. Galezo Chavarro, Diana

- ◆ Technician Responsible of the South Regional of the National Institute of Legal Medicine and Forensic Sciences
- ◆ Forensic specialist in the Regional Clinical, Psychology, Odontology and Forensic Psychiatry Group
- ◆ Expert in support to the certification process in Clinical Forensics
- ◆ Expert in Forensic Sciences and Probation Technique at the Libre University
- ◆ Expert in Search for Missing Persons in Iberoamerica

Dr. Delgado García-Carrasco, Diana Victoria

- ◆ General Dentist in Primary Care Management of the Community of Madrid
- ◆ Forensic expert specialized in Odontology by the College of Stomatologists and Odontologists of the First Region
- ◆ Forensic Odontologist at the Forensic Anatomical Institute
- ◆ Master's Degree in Dental Sciences from the Complutense University of Madrid
- ◆ Official Master's Degree in Forensic Sciences with specialization in Criminalistics and Forensic Anthropology from the Autonomous University of Madrid
- ◆ Degree in Dentistry from the Alfonso X El Sabio University
- ◆ University Expert in Forensic Dentistry and Forensic Expert in Forensic Dentistry

Dr. Lini, Priscila

- ◆ Director of the Laboratory of Bioanthropology and Forensic Anthropology of Mato Grosso do Sul
- ◆ Legal Advisor at the Federal Prosecutor's Office at the Federal University of Latin American Integration
- ◆ Technical Collaborator at the Public Defender's Office of the State of Mato Grosso do Sul
- ◆ Master's Degree in Law from the Pontifical Catholic University of Paraná
- ◆ Bachelor's Degree in Biological Sciences from Instituto Prominas
- ◆ Law Degree from State University of Western Paraná
- ◆ Specialization in Physical and Forensic Anthropology from the Institute of Professional Training in Forensic Sciences

Ms. Leyes Merino, Valeria Alejandra

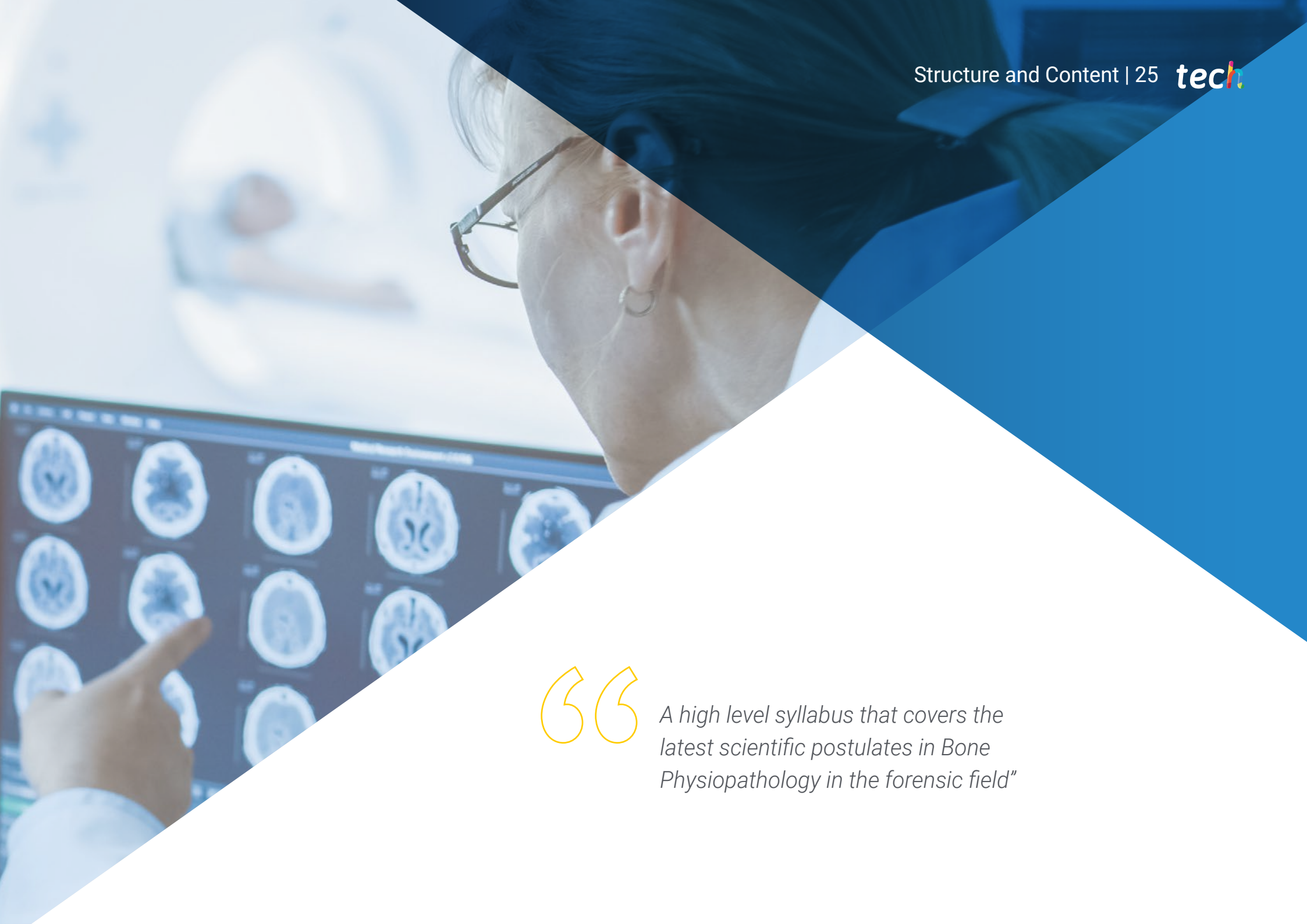- ◆ Conventional Radiology Technician in High Imaging
- ◆ Radiology Technician at Hospital Teodoro J. Schestakow
- ◆ Expert in Densitometry at the Nuclear Medicine Foundation (FUESMEN)
- ◆ Radiology Technician at the Red Cross
- ◆ Pharmacy Assistant at the Red Cross

05

Structure and Content

Under an eminently practical approach, this university program will focus on the different results of observable lesions in both the human skeleton and dentition by means of diagnostic imaging techniques. Therefore, the study plan will delve into the use of the most advanced technological equipment in the forensic area (among which highlights the Computed Tomography). Throughout the syllabus, specialists will obtain advanced skills to recognize injuries, fractures, dislocations and pathologies through visual resources. In this way, graduates will be able to carry out the most exhaustive investigations and therefore determine the real causes of death.





“

A high level syllabus that covers the latest scientific postulates in Bone Physiopathology in the forensic field”

Module 1. Diagnostic Imaging Techniques and Tools in the Forensic Context

- 1.1. Radiological Physics and its Application in the Forensic Context
 - 1.1.1. Physics Applied to Forensic Radiology
 - 1.1.2. Radiological Characterization in the Forensic Context
 - 1.1.3. Structure of Matter
- 1.2. Operation of Equipment in the Forensic Context
 - 1.2.1. X-ray Imaging System
 - 1.2.2. X-ray Tube
 - 1.2.3. Diagnostic Ultrasound
- 1.3. Forensic Use of Radiology
 - 1.3.1. Computed Tomography (CT)
 - 1.3.2. Conventional X-rays (RX)
 - 1.3.3. Ultrasound (UI)
 - 1.3.4. Magnetic Resonance
- 1.4. Forensic Radiobiology
 - 1.4.1. Human Biology
 - 1.4.2. Radiobiology
 - 1.4.3. Molecular and Cellular Radiobiology
- 1.5. Dosimetric Quantities in Forensic Contexts
 - 1.5.1. Radiation Protection
 - 1.5.2. Ionization
 - 1.5.3. Arousal
 - 1.5.4. Fluorescence
- 1.6. Digital Imaging in Forensics
 - 1.6.1. The Digital Image
 - 1.6.2. Visualization and Understanding of Images in the Forensic Field
 - 1.6.3. Artifacts
- 1.7. Forensic Computed Tomography
 - 1.7.1. Operation
 - 1.7.2. Scope
 - 1.7.3. Terminology

- 1.8. Conventional Forensic Radiobiology Equipment
 - 1.8.1. Operation
 - 1.8.2. Scope
 - 1.8.3. Terminology
- 1.9. Ultrasound in Forensic Medicine
 - 1.9.1. Operation
 - 1.9.2. Scope
 - 1.9.3. Terminology
- 1.10. Magnetic Resonance in Expert Investigation
 - 1.10.1. Operation
 - 1.10.2. Scope
 - 1.10.3. Terminology

Module 2. Forensic Radiology of the Non-Pathological and Non-Traumatic Human Skeleton

- 2.1. Forensic Radiology of the Locomotor System
 - 2.1.1. Muscular System
 - 2.1.2. Articular System
 - 2.1.3. Skeletal System
- 2.2. Forensic Radiology of the Human Skeleton
 - 2.2.1. Axial Skeleton
 - 2.2.2. Appendicular Skeleton
 - 2.2.3. Upper and Lower Extremities
- 2.3. Anatomical Plans and Axes of Movement in Forensic Investigation
 - 2.3.1. Coronal Plan
 - 2.3.2. Sagittal Plan
 - 2.3.3. Transverse Plan
 - 2.3.4. Bone Classification

- 2.4. Forensic Radiology of the Human Skull
 - 2.4.1. Facial Bones
 - 2.4.2. Neurocranium
 - 2.4.3. Associated Pathologies
- 2.5. Forensic Radiology of the Spine
 - 2.5.1. Cervical Vertebrae
 - 2.5.2. Thoracic Vertebrae
 - 2.5.3. Lumbar Vertebrae
 - 2.5.4. Sacral Vertebrae
 - 2.5.5. Associated Pathologies and Traumas
- 2.6. Forensic Radiology of the Coxal Bones
 - 2.6.1. Ilium/Ischium/Sacral Complex
 - 2.6.2. Pubic Symphysis
 - 2.6.3. Associated Pathologies and Traumas
- 2.7. Forensic Upper Extremity Radiology
 - 2.7.1. Long Bones
 - 2.7.2. Bone Complexes of the Hands
 - 2.7.3. Pathologies and Traumas
- 2.8. Forensic Radiology of the Lower Extremities
 - 2.8.1. Long Bones
 - 2.8.2. Bone Complexes of the Feet
 - 2.8.3. Pathologies and Traumas
- 2.9. Forensic Pathologies and Traumas through Diagnostic Imaging
 - 2.9.1. Congenital Diseases.
 - 2.9.2. Acquired Pathologies
 - 2.9.3. Trauma and its Variants
- 2.10. Interpretation of Radiographic Images in the Forensic Field
 - 2.10.1. Radiolucent Bodies
 - 2.10.2. Radiopaque Bodies
 - 2.10.3. Gray Scales

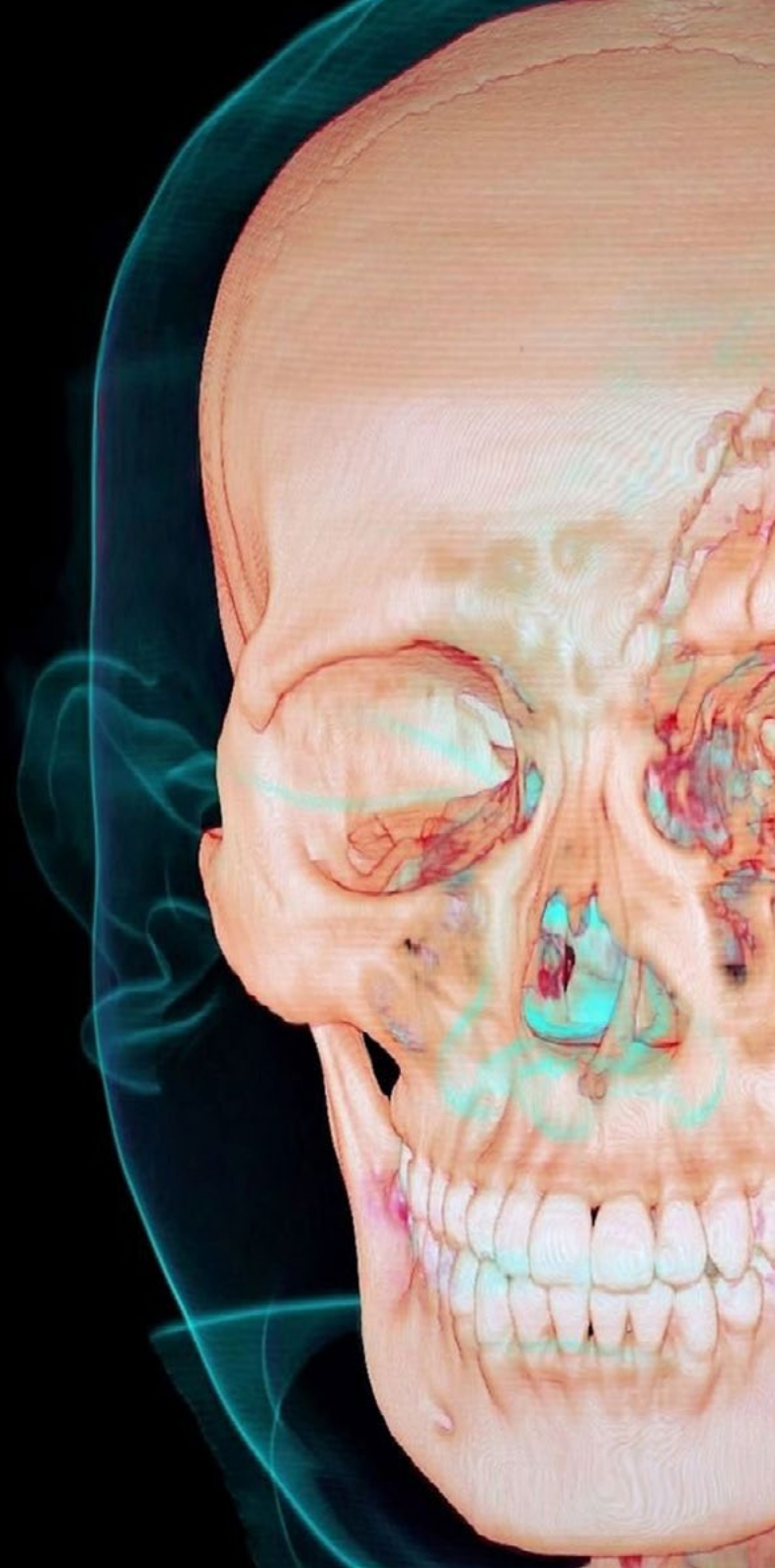Module 3. Forensic Radiology of the Human Skeleton in Phases of Biological Maturation

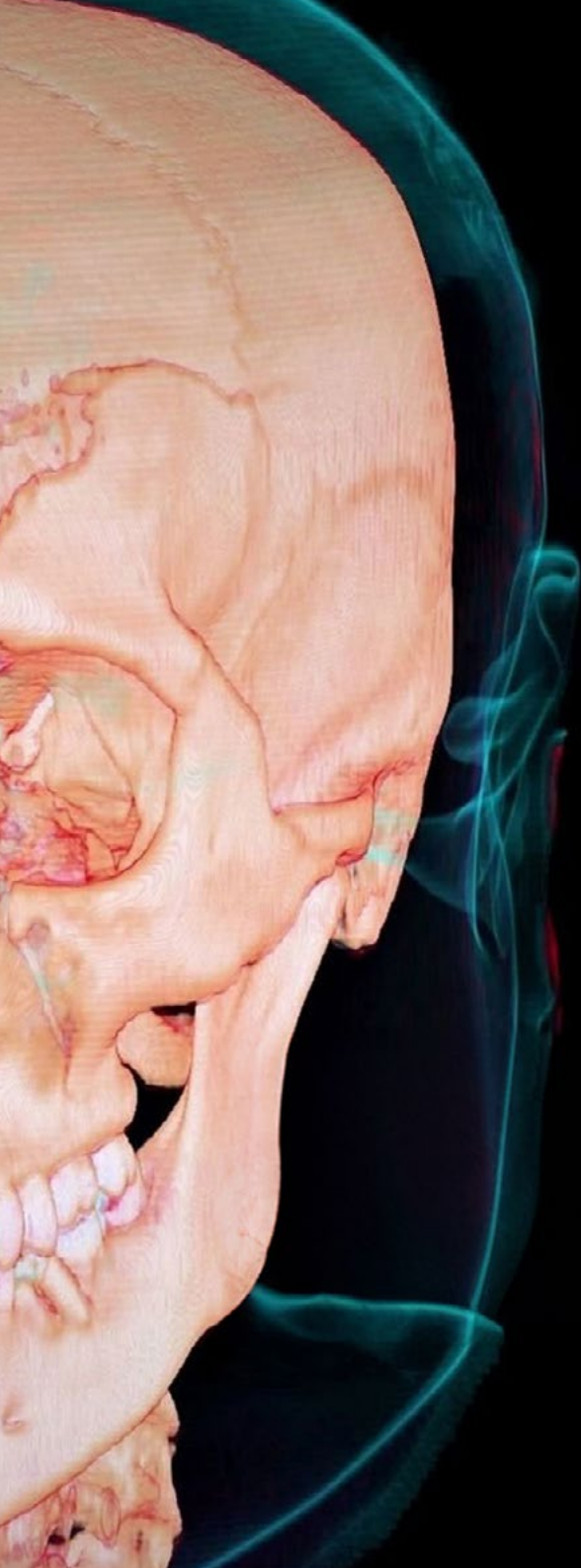- 3.1. Bone Physiopathology in the Forensic Context
 - 3.1.1. Functions
 - 3.1.2. Composition - Bone Tissue
 - 3.1.3. Cellular Component
 - 3.1.3.1. Bone-Forming Cells (Osteoblasts)
 - 3.1.3.2. Bone Destroyers (Osteoclasts)
 - 3.1.3.3. Mature Bone Cells (Osteocytes)
- 3.2. Osteogenesis in Individuals in the Forensic Context
 - 3.2.1. Membranous Ossification Pathway
 - 3.2.2. Chondral Ossification Pathway
 - 3.2.3. Periosteum
- 3.3. Bone Vascularization in the Forensic Context
 - 3.3.1. Main Pathway
 - 3.3.2. Epiphyseal Pathway
 - 3.3.3. Metaphyseal Pathway
 - 3.3.4. Periosteal Arterial Pathway
- 3.4. Bone Growth in the Forensic Context
 - 3.4.1. Width
 - 3.4.2. Length
 - 3.4.3. Associated Pathologies
- 3.5. Forensic Radiology of Pathologies in Developing Individuals
 - 3.5.1. Congenital Diseases.
 - 3.5.2. Acquired Pathologies
 - 3.5.3. Trauma and its Variants
- 3.6. Bone Diseases Through Diagnostic Imaging in the Forensic Context
 - 3.6.1. Osteoporosis
 - 3.6.2. Bone Cancer
 - 3.6.3. Osteomyelitis
 - 3.6.4. Osteogenesis Imperfecta
 - 3.6.5. Rickets

- 3.7. Forensic Radiology of the Child Skull
 - 3.7.1. Embryonic, Fetal and Neonatal Formation.
 - 3.7.2. Fontanelles and Fusion Phases
 - 3.7.3. Facial and Dental Development
- 3.8. Forensic Radiobiological Osteology in the Adolescent
 - 3.8.1. Sexual Dimorphism and Bone Growth
 - 3.8.2. Bone Changes Resulting from Hormonal Action
 - 3.8.3. Juvenile Growth Retardation and Metabolic Problems
- 3.9. Trauma and Categories of Childhood Fractures in Forensic Diagnostic Imaging
 - 3.9.1. Frequent Traumas in Infantile Long Bones
 - 3.9.2. Frequent Traumas in Infantile Flat Bones
 - 3.9.3. Trauma Resulting from Aggression and Mistreatment
- 3.10. Radiology and Diagnostic Imaging Techniques in Forensic Pediatrics
 - 3.10.1. Radiology for Neonates and Infants
 - 3.10.2. Radiology for Children in Early Childhood
 - 3.10.3. Radiology for Adolescents and Juveniles

Module 4. Forensic Maxillofacial Radiology

- 4.1. Forensic Radiological Interpretation of Head and Neck: Skull Bones
 - 4.1.1. Forensic Radiological Interpretation of the External Paired Bones: Temporal and Parietal
 - 4.1.2. Forensic Radiological Interpretation of the External Odd Bones: Frontal, Occipital
 - 4.1.3. Forensic Radiological Interpretation of the Internal Odd Bones: Ethmoid and Sphenoid.
- 4.2. Forensic Radiological Interpretation of Head and Neck: Bones of the Face
 - 4.2.1. Forensic Radiological Interpretation of the Vomer
 - 4.2.2. Forensic Radiologic Interpretation of the Inferior Turbinate
 - 4.2.3. Forensic radiological Interpretation of the Zygomatic or Malar Bone.
 - 4.2.4. Forensic Radiological Interpretation of the Nasal Lachrymal Bone
- 4.3. Forensic Radiological Interpretation of Head and Neck: Oral Cavity Bones
 - 4.3.1. Forensic Radiological Interpretation of the Upper Jaw.
 - 4.3.2. Forensic Radiological Interpretation of the Lower Maxilla or Mandible
 - 4.3.3. Forensic Radiological Interpretation of the Dental Parts





- 4.4. Radiological Interpretation of Head and Neck: Sutures
 - 4.4.1. Forensic Radiological Interpretation of the Upper Jaw.
 - 4.4.2. Forensic Radiological Interpretation of the Lower Maxilla or Mandible
 - 4.4.3. Forensic Radiological Interpretation of the Dental Parts
- 4.5. Forensic Radiological Interpretation of Head and Neck: Facial Buttresses Sutures.
 - 4.5.1. Forensic Radiological Interpretation of the Horizontal Buttresses
 - 4.5.2. Forensic Radiological Interpretation of Vertical Buttresses
 - 4.5.3. Abnormalities
- 4.6. Forensic Radiography of the Head and Neck: Extraoral Radiographs
 - 4.6.1. Lateral Radiographs
 - 4.6.2. Fronto-Occipital Radiographs
 - 4.6.3. Occipito-Frontal Radiographs
 - 4.6.4. Orthopantomography
- 4.7. Forensic Radiography of Head and Neck Anatomical Accidents: Intraoral Radiographs
 - 4.7.1. Occlusal Radiographs
 - 4.7.2. Periapical Radiographs
 - 4.7.3. Bitewing Radiographs
 - 4.7.4. Relevant Elements Observed in Intraoral Radiographs
- 4.8. Forensic Radiographic Interpretation of Head and Neck Anatomical Features: Extraoral Radiography
 - 4.8.1. Lateral Radiography
 - 4.8.2. Fronto-Occipital Radiography
 - 4.8.3. Occipito-Frontal Radiography
 - 4.8.4. Orthopantomography
- 4.9. Forensic Radiographic Interpretation of Head and Neck Anatomical Features: Intraoral Radiography
 - 4.9.1. Occlusal Radiography
 - 4.9.2. Periapical Radiography
 - 4.9.3. Bitewing Radiograph
- 4.10. Forensic Radiographic Interpretation of Head and Neck Anatomical Features: Other Radiographic Techniques
 - 4.10.1. Computerized Axial Tomography
 - 4.10.2. CBCT
 - 4.10.3. MRI

Module 5. Forensic Radiology in Human Identification

- 5.1. Human Identification in the Forensic Context
 - 5.1.1. In Police Cases
 - 5.1.2. In Judicial Cases
 - 5.1.3. In Crimes Against Humanity and War Crimes
 - 5.1.4. In Major Disasters
- 5.2. The Human Skeleton and Biological Identification (I): Osteological Sexual Characterization in Adults
 - 5.2.1. Sexual Characterization Through the Skull
 - 5.2.2. Sexual Characterization Through the Hip
 - 5.2.3. Osteological Sex Characterization from Other Bones
- 5.3. The Human Skeleton and Biological Identification (II): Osteological Sexual Characterization in Individuals in Maturing Stages
 - 5.3.1. Sexual Characterization Through the Skull
 - 5.3.2. Sexual Characterization Through the Hip
 - 5.3.3. Osteological Sex Characterization from Other Bones
- 5.4. The Human Skeleton and Biological Identification (III): Determination of Age at Death in Adult Individuals
 - 5.4.1. Age Determination from the Closure of Bone Epiphyses and Cranial Sutures
 - 5.4.2. Age Determination from Cartilage Ossification
 - 5.4.3. Age Determination from the Modification of Bone Regions
- 5.5. The Human Skeleton and Biological Identification (IV): Age Determination at Death in Maturing Individuals
 - 5.5.1. Determination of age from Morphometrics
 - 5.5.2. Age Determination by Bone Birth
 - 5.5.3. Age Determination by Epiphyseal and Fontanel Closure
- 5.6. The Human Skeleton and Biological Identification (V): Determination of Stature and Muscular Build
 - 5.6.1. Estimation of Stature of Anatomical Nature
 - 5.6.2. Estimation of Stature of Physiological Nature
 - 5.6.3. Bone Biomechanics and Adaptation to Physical Activity
 - 5.6.4. Development of Muscular Complexion

- 5.7. Human Dentition for the Calculation of Age at Death
 - 5.7.1. The Dentition in Maturing Individuals
 - 5.7.2. Dentition in Adult Individuals
 - 5.7.3. Dental Alterations and Pathologies
- 5.8. Biomechanics and Mechanical Forces Applied to Bone Trauma
 - 5.8.1. Osteological Growth and Development
 - 5.8.2. Mechanical Forces Applied to the Human Skeleton
 - 5.8.3. Bone Adaptation to Exercise
- 5.9. Bone Trauma due to Temporality
 - 5.9.1. Characterization of Antemortem Traumas
 - 5.9.2. Characterization of Perimortem Traumas
 - 5.9.3. Characterization of Postmortem Trauma
- 5.10. Trauma by Type of Injury
 - 5.10.1. Classification by Type of Injury
 - 5.10.2. Classification by Type of Weapon
 - 5.10.3. Classification by Type of Object and Structure

Module 6. Radiodiagnosis of Pathologies Related to Forensic Investigation

- 6.1. Classification of Traumatic Fractures in the Forensic Context
 - 6.1.1. Classification According to Skin Condition
 - 6.1.2. Classification According to Location
 - 6.1.3. Classification According to Fracture Trace
- 6.2. Stages of Bone Repair in the Forensic Context
 - 6.2.1. Inflammatory Phase
 - 6.2.2. Repair Phase
 - 6.2.3. Remodelling Phase
- 6.3. Child Maltreatment and its Radiodiagnosis in a Forensic Context
 - 6.3.1. Simple Radiography
 - 6.3.2. Axial Tomography
 - 6.3.3. Magnetic Resonance

- 6.4. Illegal Transport of Narcotics and Radiodiagnostics in a Forensic Context
 - 6.4.1. Simple Radiography
 - 6.4.2. Axial Tomography
 - 6.4.3. Magnetic Resonance
- 6.5. Simple Radiographic Technique for Identification of Alterations within a Forensic Context
 - 6.5.1. Cranial Pathologies
 - 6.5.2. Thoracic Pathologies
 - 6.5.3. Extremity Pathologies
- 6.6. Ultrasound Technique for Identification of Pathologies within a Forensic Context
 - 6.6.1. Ultrasound
 - 6.6.2. Obstetric
 - 6.6.3. Wall
- 6.7. Computed Tomography and Identification of Pathologies in a Forensic Context
 - 6.7.1. Cranial
 - 6.7.2. Wall
 - 6.7.3. Ultrasound
- 6.8. Magnetic Resonance Imaging and Pathology Identification in a Forensic Context
 - 6.8.1. Cranial
 - 6.8.2. Wall
 - 6.8.3. Ultrasound
- 6.9. Diagnostic Angiography in a Forensic Context
 - 6.9.1. Cranial
 - 6.9.2. Ultrasound
 - 6.9.3. Extremities
- 6.10. Virtopsia, Radiology in Forensic Medicine
 - 6.10.1. Resonance
 - 6.10.2. Tomography
 - 6.10.3. Radiography

Module 7. Forensic Radiological Techniques of Bone and Dental Trauma with Blunt Objects

- 7.1. Classification of Blunt Profile Injury Elements
 - 7.1.1. Blunt Weapons
 - 7.1.2. Blunt Objects
 - 7.1.3. Blunt Mechanical Force Injuries
 - 7.1.4. Structural Injuries
 - 7.1.5. Short Blunt Injuries
- 7.2. Injury Mechanics of Blunt Elements
 - 7.2.1. Blunt Weapons
 - 7.2.2. Blunt Objects
 - 7.2.3. Blunt Mechanical Force Injuries
 - 7.2.4. Injuries Through Structures
 - 7.2.5. Short Blunt Injuries
- 7.3. Injury Typologies of Blunt weapons
 - 7.3.1. Superficial Injuries
 - 7.3.2. Deep Injuries
 - 7.3.3. Total or Partial Amputation Injuries
- 7.4. Types of Injuries Caused by Blunt Objects
 - 7.4.1. Superficial Injuries
 - 7.4.2. Deep Injuries
 - 7.4.3. Total or Partial Amputation Injuries
- 7.5. Injury Typologies Due to Blunt Injury Mechanics
 - 7.5.1. Superficial Injuries
 - 7.5.2. Deep Injuries
 - 7.5.3. Total or Partial Amputation Injuries
- 7.6. Injury Typologies of Blunt Structures and Short-Contusive Elements
 - 7.6.1. Superficial Injuries
 - 7.6.2. Deep Injuries
 - 7.6.3. Total or Partial Amputation Injuries

- 7.7. Marks on the Skeleton of Injuries Due to Blunt Mechanics
 - 7.7.1. Blunt Weapons
 - 7.7.2. Blunt Objects
 - 7.7.3. Blunt Mechanical Force Injuries
 - 7.7.4. Injuries Through Structures
 - 7.7.5. Short Blunt Injuries
- 7.8. Radiological Techniques for the Study of Blunt Force Injuries
 - 7.8.1. X-Ray
 - 7.8.2. Computerized Axial Tomography
 - 7.8.3. Other Radiographic Techniques
- 7.9. Radiobiological Techniques for the Study of Injuries of Blunt Objects and Structures
 - 7.9.1. X-Ray
 - 7.9.2. Computerized Axial Tomography
 - 7.9.3. Other Radiographic Techniques
- 7.10. Radiobiological Techniques for the Study of Blunt Mechanical Injuries and Short Blunt Elements
 - 7.10.1. X-Ray
 - 7.10.2. Computerized Axial Tomography
 - 7.10.3. Other Radiographic Techniques

Module 8. Forensic Radiology of Trauma with Sharp and Cutting Elements

- 8.1. Classification of Sharp Weapons
 - 8.1.1. Cutting Weapons
 - 8.1.2. Sharp Weapons
 - 8.1.3. Sharps
- 8.2. Injurious Mechanics of Edged Weapons
 - 8.2.1. Cutting Weapons
 - 8.2.3. Sharp Weapons
 - 8.2.4. Sharps
- 8.3. Types of Injuries Caused by Cutting Weapons
 - 8.3.1. Superficial Injuries
 - 8.3.2. Deep Injuries
 - 8.3.3. Total or Partial Amputation Injuries
- 8.4. Injury Typologies of Sharp-Edged Weapons by Sharp Weapons
 - 8.4.1. Superficial Injuries
 - 8.4.2. Deep Injuries
 - 8.4.3. Total or Partial Amputation Injuries
- 8.5. Injury Typologies of Sharp-Edged Weapons by Sharps
 - 8.5.1. Superficial Injuries
 - 8.5.2. Deep Injuries
 - 8.5.3. Total or Partial Amputation Injuries
- 8.6. Skeletal Marks from Sharp-Edged Weapon Injuries
 - 8.6.1. Cutting Weapons
 - 8.6.2. Sharp Weapons
 - 8.6.3. Sharps
- 8.7. Radiological Techniques for the Study of Cutting Weapon Injuries
 - 8.7.1. X-Ray
 - 8.7.2. Computerized Axial Tomography
 - 8.7.3. Other Radiographic Techniques
- 8.8. Radiological Techniques for the Study of Sharps Injuries
 - 8.8.1. X-Ray
 - 8.8.2. Computerized Axial Tomography
 - 8.8.3. Other Radiographic Techniques
- 8.9. Radiological Techniques for the Study of Sharps Injuries
 - 8.9.1. X-Ray
 - 8.9.2. Computerized Axial Tomography
 - 8.9.3. Other Radiographic Techniques
- 8.10. Analysis of Lesions at the Maturation Stage and in Animals
 - 8.10.1. Cutting Lesions in Individuals in Early Stages of Maturation
 - 8.10.2. Cut Marks on Individuals in Late Stages of Biological Maturation
 - 8.10.3. Cutting Injuries in Animals

Module 9. Radiology of Firearms and Explosives Trauma in Forensic Investigation

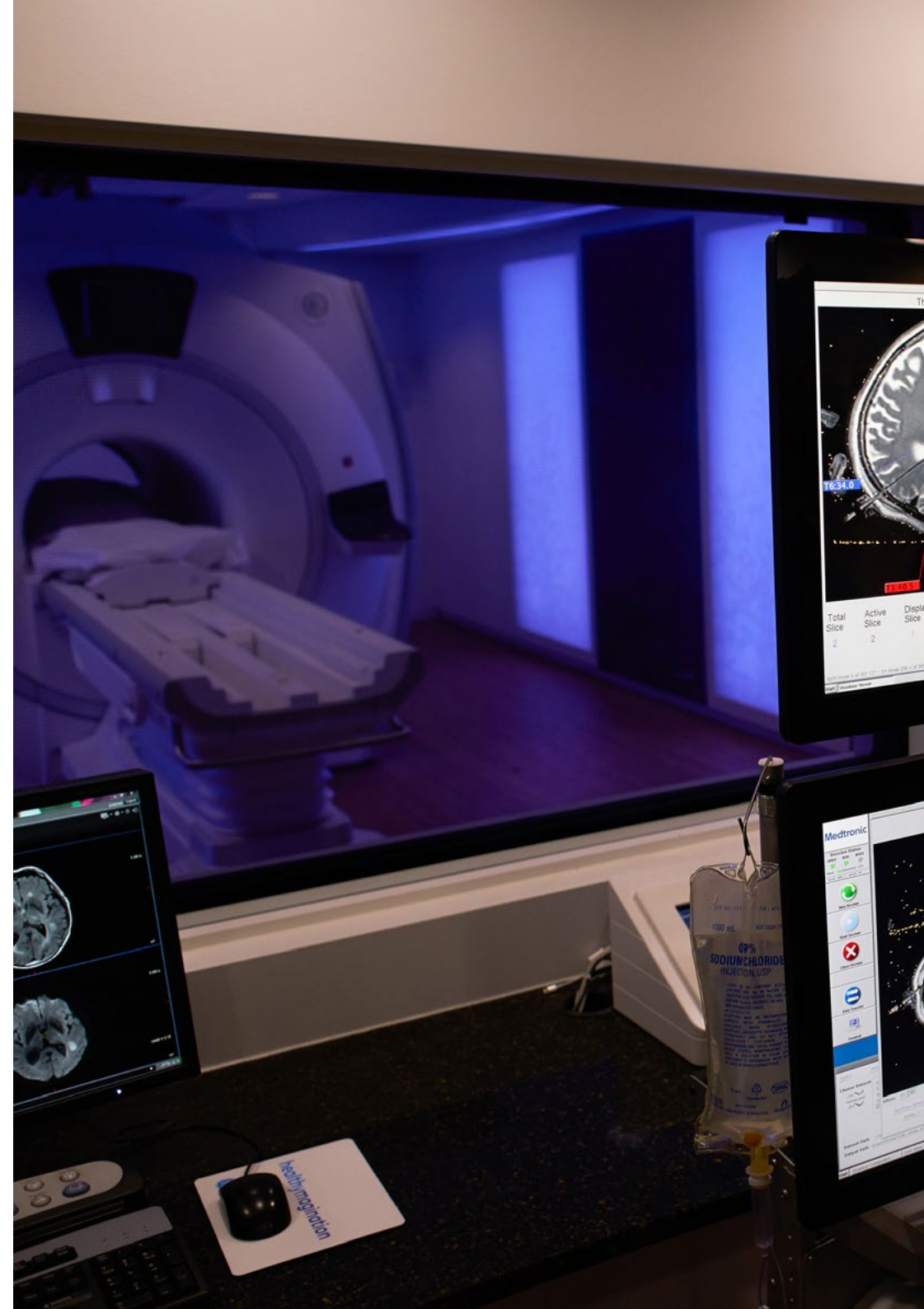- 9.1. Firearms and Projectiles
 - 9.1.1. Classification of Firearms
 - 9.1.2. Elements that Compose a Firearm
 - 9.1.3. Structure of the Firearm
 - 9.1.4. Firearm Projectiles
- 9.2. Characterization of Wounds and Firearm Projectile Trajectory
 - 9.2.1. Entrance Orifice
 - 9.2.2. Trajectory
 - 9.2.3. Outlet Orifice
- 9.3. X-ray Technique and Firearm Projectiles
 - 9.3.1. Number of Projectiles
 - 9.3.2. Probable Trajectory
 - 9.3.3. Probable Caliber
 - 9.3.4. Type of Firearm
- 9.4. Axial Tomography and Firearm Projectiles
 - 9.4.1. Number of Projectiles
 - 9.4.2. Trajectory
 - 9.4.3. Type of Weapons Used
- 9.5. Ultrasound and Firearm Projectile
 - 9.5.1. Number of Projectiles
 - 9.5.2. Trajectory
 - 9.5.3. Type of Weapons Used
- 9.6. Virtual Autopsy in Deaths Caused by Firearm Projectile Wounds
 - 9.6.1. Simple Radiography
 - 9.6.2. Computerized Axial Tomography
 - 9.6.3. Magnetic Resonance
- 9.7. Explosives
 - 9.7.1. Typologies of Explosive Elements
 - 9.7.2. Categorization
 - 9.7.3. Mechanics of Explosions

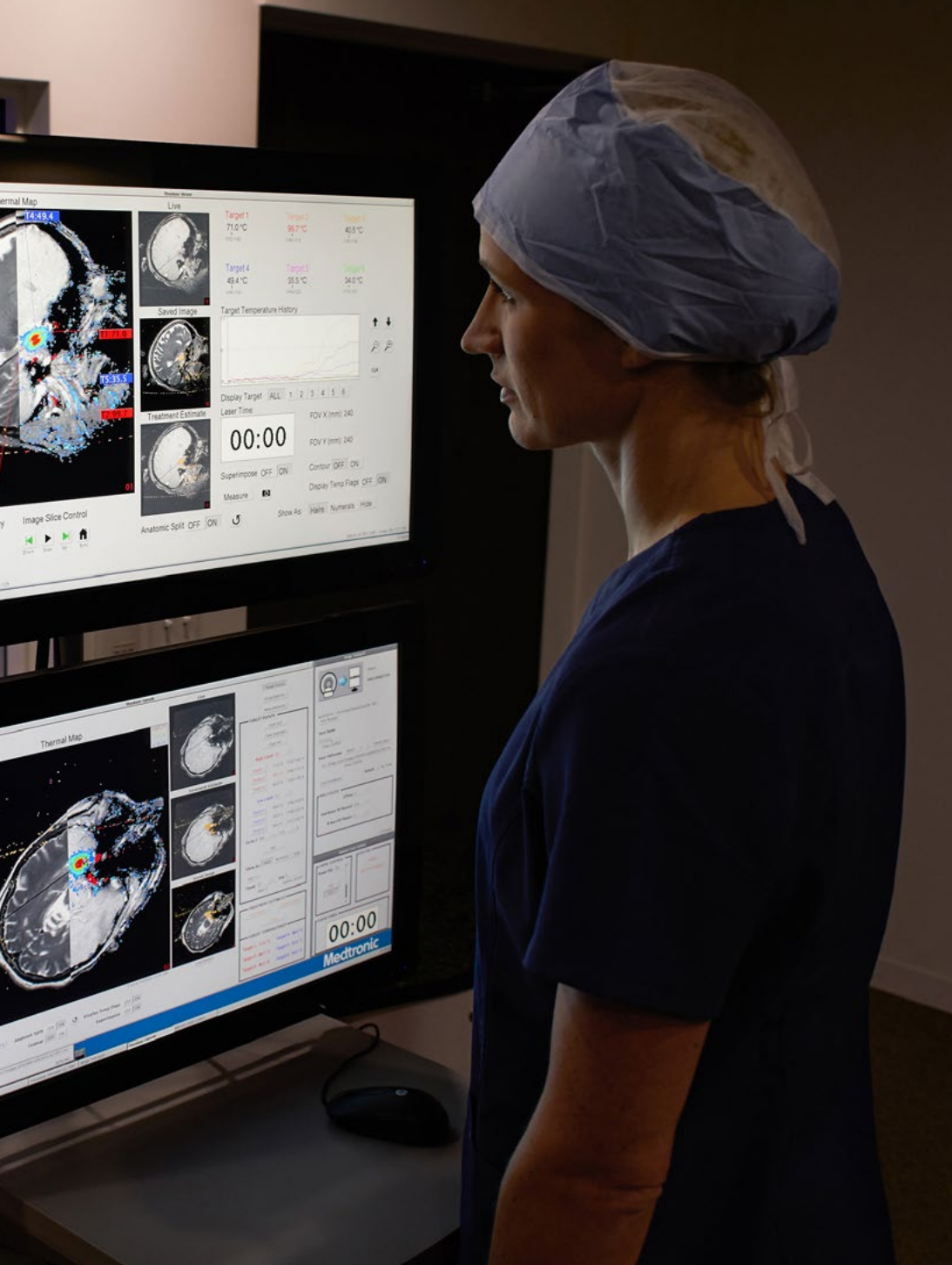- 9.8. Classification of Blast Injuries
 - 9.8.1. Primary
 - 9.8.2. Secondary
 - 9.8.3. Tertiary
 - 9.8.4. Quaternary
- 9.9. Radiodiagnostic Imaging in the Search for and Retrieval of Evidence
 - 9.9.1. Simple Radiography
 - 9.9.2. Computerized Axial Tomography
 - 9.9.3. Magnetic Resonance
- 9.10. Radiological Assessment of Blast Injuries
 - 9.10.1. Cranial
 - 9.10.2. Cervical
 - 9.10.3. Chest
 - 9.10.4. Abdomen
 - 9.10.5. Extremities

Module 10. Forensic Radiodiagnosis of Maxillofacial Trauma

- 10.1. Forensic Maxillofacial Trauma: Fractures of the Upper Third of the Face
 - 10.1.1. Fractures of the Frontal Bone
 - 10.1.2. Fractures of the Walls of the Frontal Sinuses
 - 10.1.3. Fractures of the Temporal/Parietal Bone
- 10.2. Forensic Maxillofacial Trauma: Fractures of the Middle Third of the Face
 - 10.2.1. Nasal Fractures
 - 10.2.2. Orbital Fractures
 - 10.2.3. Fractures of the Naso-Orbito-Ethmoidal Complex
 - 10.2.4. Fractures of the Zygomatic Bone
- 10.3. Forensic Maxillofacial Trauma: Fractures of the Lower Third of the Face
 - 10.3.1. Fracture of the Mandibular Symphysis / Parasymphysis
 - 10.3.2. Fracture of the Mandibular Body
 - 10.3.3. Mandibular Angle Fracture
 - 10.3.4. Mandibular Ramus Fracture
 - 10.3.5. Fracture of the Mandibular Condyle

- 10.4. Forensic Maxillofacial Trauma: Le Fort Fractures
 - 10.4.1. Le Fort I Fractures
 - 10.4.2. Le Fort II Fractures
 - 10.4.3. Le Fort III Fractures
 - 10.4.4. Le Fort IV Fractures
- 10.5. Forensic Maxillofacial Trauma: Alveolodental Fractures
 - 10.5.1. Coronary Fracture
 - 10.5.2. Corono-Radicular Fracture
 - 10.5.3. Root Fracture
 - 10.5.4. Alveolar Fracture
 - 10.5.5. Avulsion
- 10.6. Radiographic Techniques for the Study of Maxillofacial Trauma in the Forensic Context.
 - 10.6.1. X-Ray
 - 10.6.2. Computerized Axial Tomography
 - 10.6.3. Other Radiographic Techniques
- 10.7. Radiographic Techniques for the Study of Alveolar Tooth Trauma in the Forensic Context
 - 10.7.1. X-Ray
 - 10.7.2. Computerized Axial Tomography
 - 10.7.3. Other Radiological Techniques
- 10.8. Radiographic Interpretation of Maxillofacial Trauma in the Forensic Context: Isolated Fractures.
 - 10.8.1. Radiographic Interpretation of Trauma to the Upper Third of the Face.
 - 10.8.2. Radiographic Interpretation of Trauma of the Middle Third of the Face
 - 10.8.3. Radiographic Interpretation of Trauma of the Lower Third of the Face





- 10.9. Radiographic Interpretation of Maxillofacial Trauma Within the Forensic Context Le Fort Fractures
 - 10.9.1. Radiographic Interpretation in Le Fort I Fractures
 - 10.9.2. Radiographic Interpretation in Le Fort II Fractures
 - 10.9.3. Radiographic Interpretation in Le Fort III Fractures
 - 10.9.4. Radiographic Interpretation in Le Fort IV Fractures
- 10.10. Radiographic Techniques for the Study of Alveolar Tooth Trauma in the Forensic Context
 - 10.10.1. Coronary Fracture
 - 10.10.2. Corono-Radicular Fracture
 - 10.10.3. Alveolar Fracture
 - 10.10.4. Root Fracture
 - 10.10.5. Avulsion

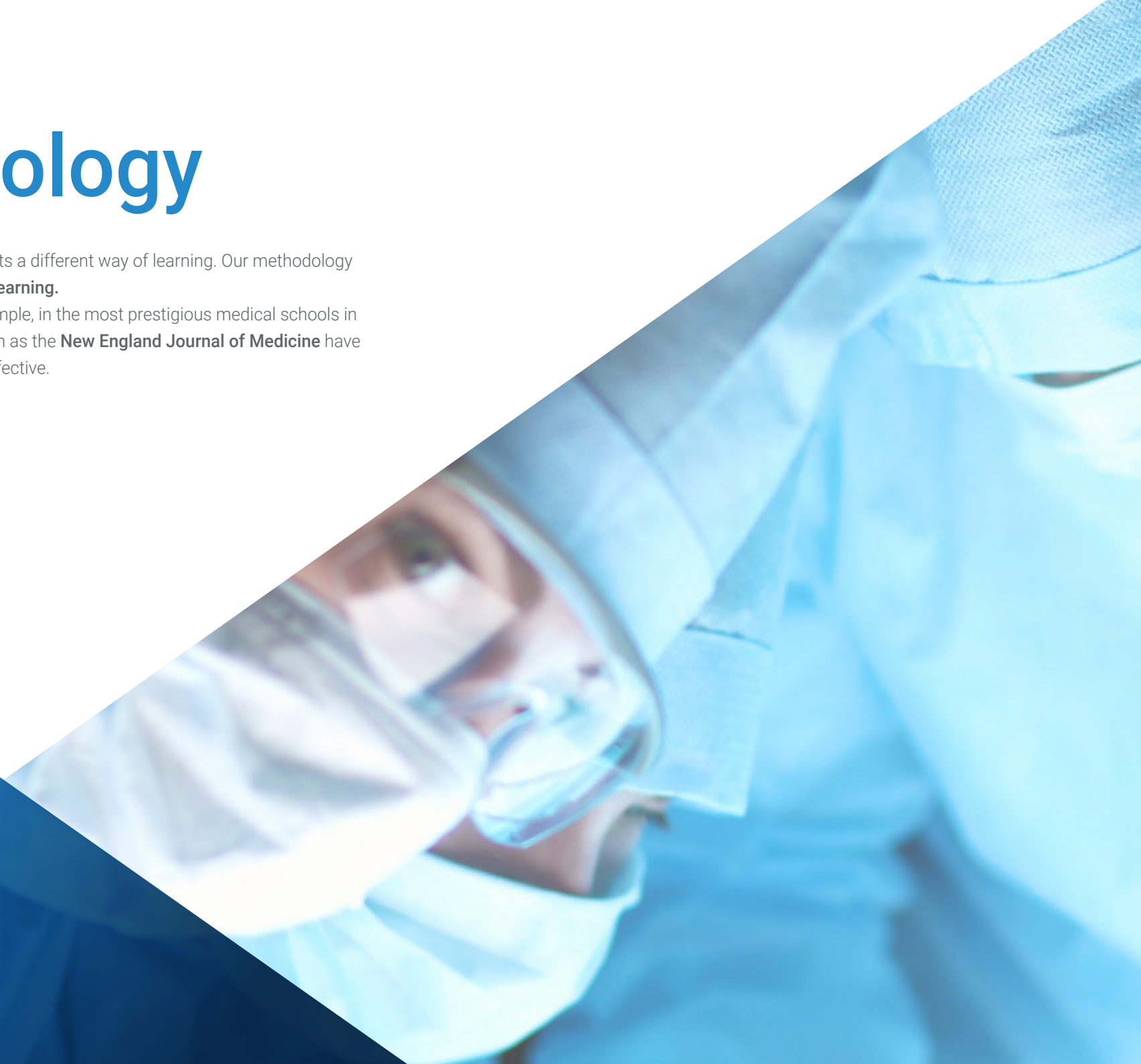“TECH gives you access to one of the best virtual libraries, so that you can enjoy continuous updating. Enroll now!”

06

Methodology

This academic program offers students a different way of learning. Our methodology uses a cyclical learning approach: **Relearning**.

This teaching system is used, for example, in the most prestigious medical schools in the world, and major publications such as the **New England Journal of Medicine** have considered it to be one of the most effective.



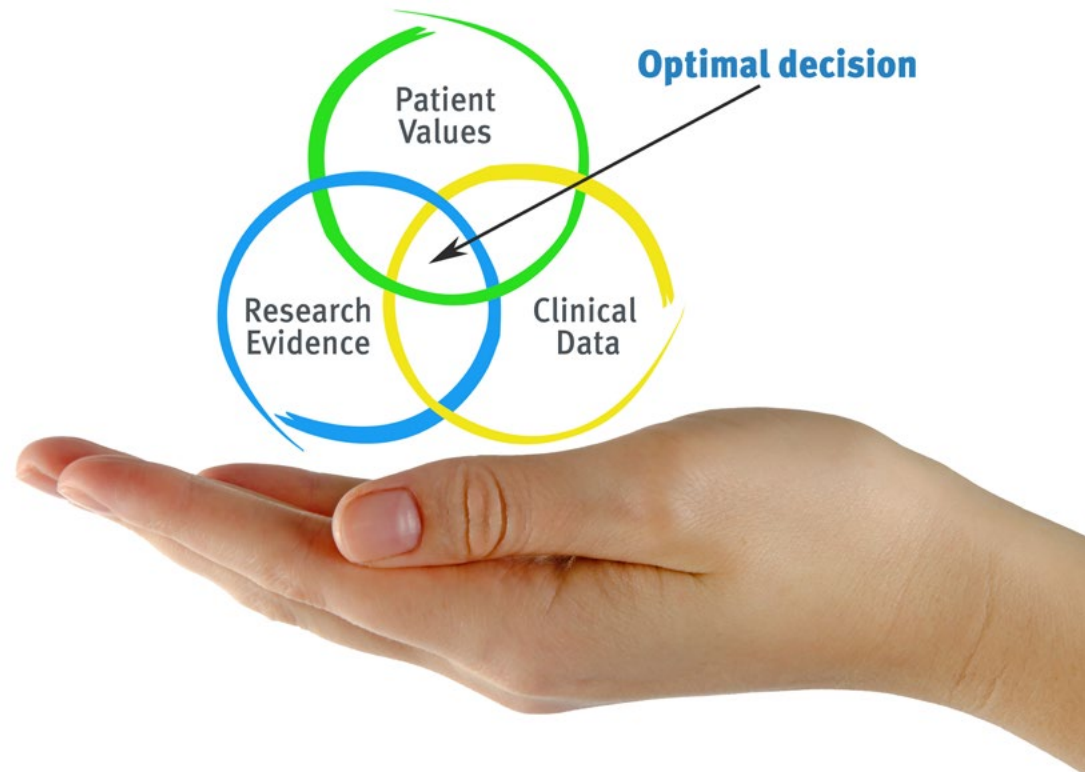“

Discover Relearning, a system that abandons conventional linear learning, to take you through cyclical teaching systems: a way of learning that has proven to be extremely effective, especially in subjects that require memorization"

At TECH we use the Case Method

What should a professional do in a given situation? Throughout the program, students will face multiple simulated clinical cases, based on real patients, in which they will have to do research, establish hypotheses, and ultimately resolve the situation. There is an abundance of scientific evidence on the effectiveness of the method. Specialists learn better, faster, and more sustainably over time.

With TECH you will experience a way of learning that is shaking the foundations of traditional universities around the world.



According to Dr. Gérvas, the clinical case is the annotated presentation of a patient, or group of patients, which becomes a "case", an example or model that illustrates some peculiar clinical component, either because of its teaching power or because of its uniqueness or rarity. It is essential that the case is based on current professional life, trying to recreate the real conditions in the physician's professional practice.

“

Did you know that this method was developed in 1912, at Harvard, for law students? The case method consisted of presenting students with real-life, complex situations for them to make decisions and justify their decisions on how to solve them. In 1924, Harvard adopted it as a standard teaching method”

The effectiveness of the method is justified by four fundamental achievements:

1. Students who follow this method not only achieve the assimilation of concepts, but also a development of their mental capacity, through exercises that evaluate real situations and the application of knowledge.
2. Learning is solidly translated into practical skills that allow the student to better integrate into the real world.
3. Ideas and concepts are understood more efficiently, given that the example situations are based on real-life.
4. Students like to feel that the effort they put into their studies is worthwhile. This then translates into a greater interest in learning and more time dedicated to working on the course.

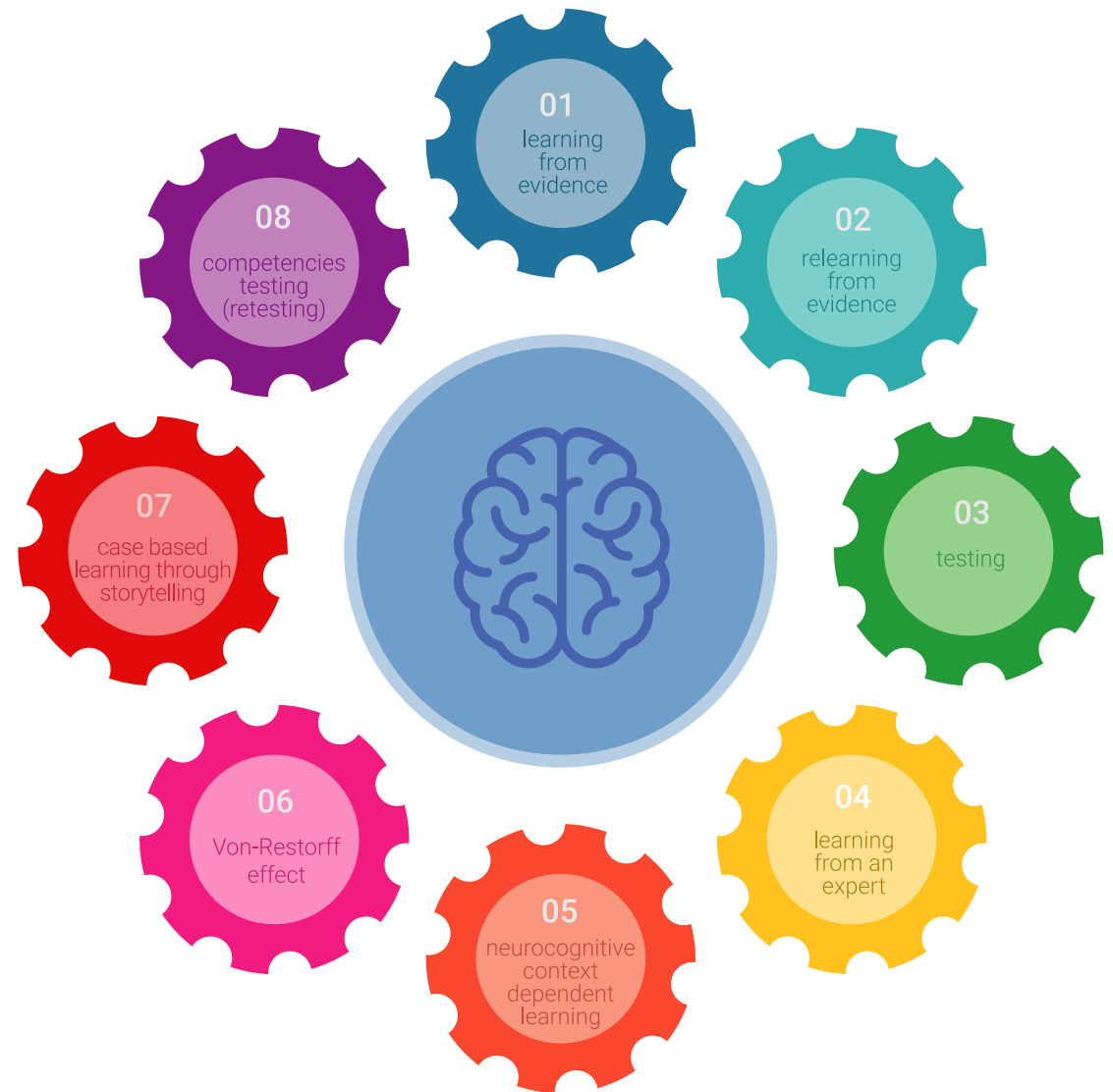


Relearning Methodology

At TECH we enhance the case method with the best 100% online teaching methodology available: Relearning.

This university is the first in the world to combine the study of clinical cases with a 100% online learning system based on repetition, combining a minimum of 8 different elements in each lesson, a real revolution with respect to the mere study and analysis of cases.

Professionals will learn through real cases and by resolving complex situations in simulated learning environments. These simulations are developed using state-of-the-art software to facilitate immersive learning.



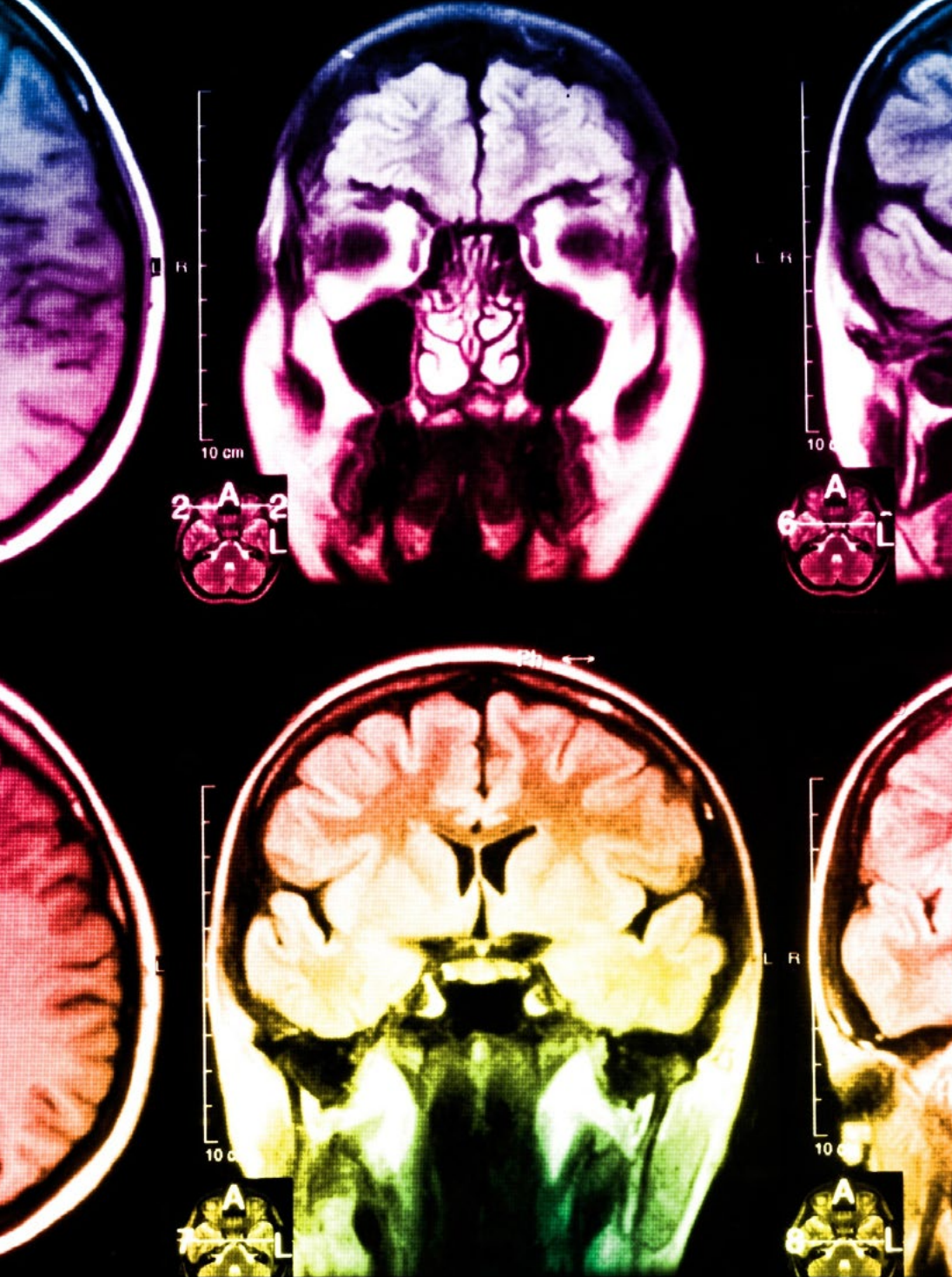At the forefront of world teaching, the Relearning method has managed to improve the overall satisfaction levels of professionals who complete their studies, with respect to the quality indicators of the best online university (Columbia University).

With this methodology, more than 250,000 physicians have been trained with unprecedented success in all clinical specialties regardless of surgical load. Our pedagogical methodology is developed in a highly competitive environment, with a university student body with a strong socioeconomic profile and an average age of 43.5 years old.

Relearning will allow you to learn with less effort and better performance, involving you more in your specialization, developing a critical mindset, defending arguments, and contrasting opinions: a direct equation to success.

In our program, learning is not a linear process, but rather a spiral (learn, unlearn, forget, and re-learn). Therefore, we combine each of these elements concentrically.

The overall score obtained by TECH's learning system is 8.01, according to the highest international standards.



This program offers the best educational material, prepared with professionals in mind:



Study Material

All teaching material is produced by the specialists who teach the course, specifically for the course, so that the teaching content is highly specific and precise.

These contents are then applied to the audiovisual format, to create the TECH online working method. All this, with the latest techniques that offer high quality pieces in each and every one of the materials that are made available to the student.



Surgical Techniques and Procedures on Video

TECH introduces students to the latest techniques, the latest educational advances and to the forefront of current medical techniques. All of this in direct contact with students and explained in detail so as to aid their assimilation and understanding. And best of all, you can watch the videos as many times as you like.



Interactive Summaries

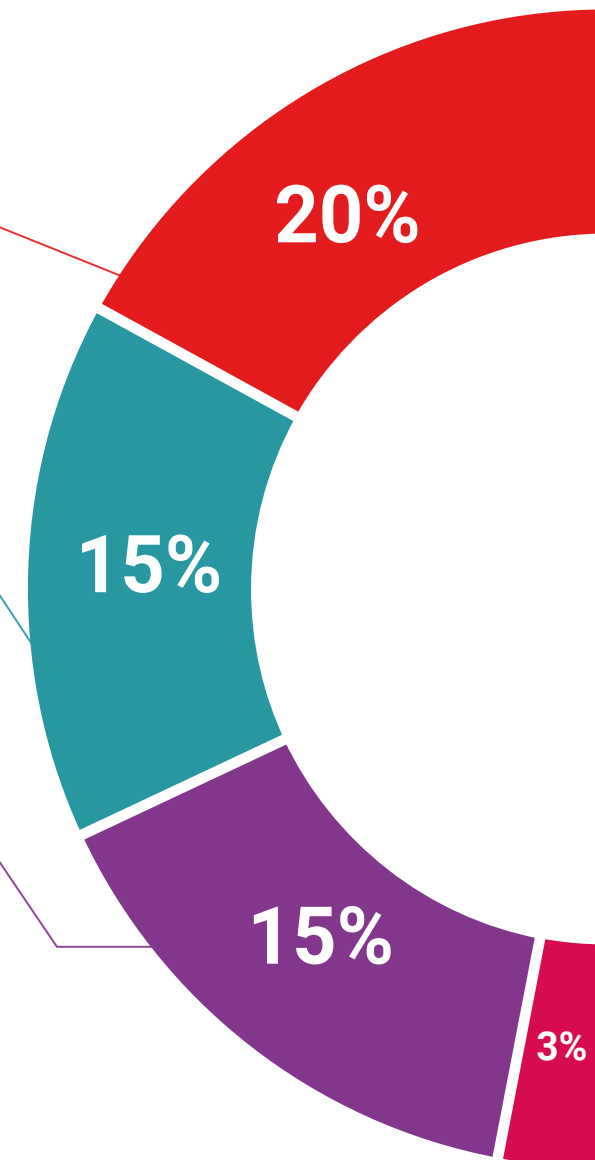
The TECH team presents the contents attractively and dynamically in multimedia lessons that include audio, videos, images, diagrams, and concept maps in order to reinforce knowledge.

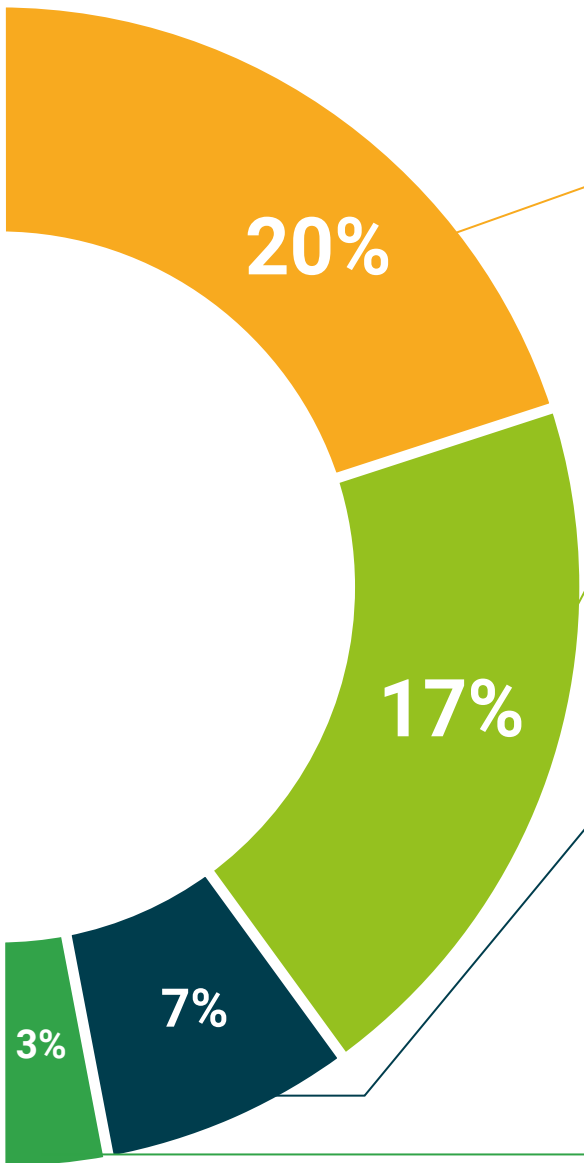
This exclusive educational system for presenting multimedia content was awarded by Microsoft as a "European Success Story".



Additional Reading

Recent articles, consensus documents and international guidelines, among others. In TECH's virtual library, students will have access to everything they need to complete their course.





Expert-Led Case Studies and Case Analysis

Effective learning ought to be contextual. Therefore, TECH presents real cases in which the expert will guide students, focusing on and solving the different situations: a clear and direct way to achieve the highest degree of understanding.



Testing & Retesting

We periodically evaluate and re-evaluate students' knowledge throughout the program, through assessment and self-assessment activities and exercises, so that they can see how they are achieving their goals.



Classes

There is scientific evidence on the usefulness of learning by observing experts. The system known as Learning from an Expert strengthens knowledge and memory, and generates confidence in future difficult decisions.



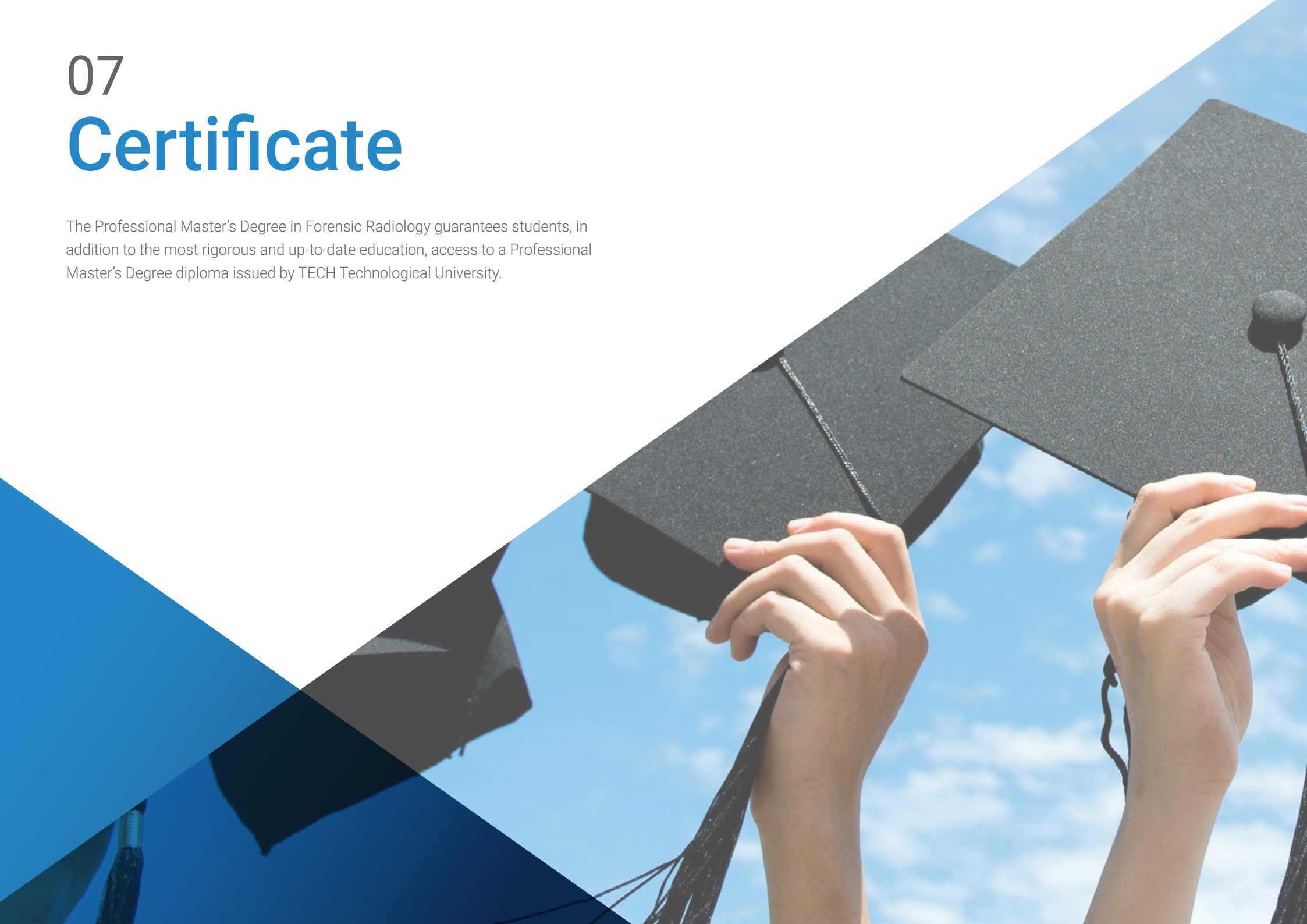Quick Action Guides

TECH offers the most relevant contents of the course in the form of worksheets or quick action guides. A synthetic, practical, and effective way to help students progress in their learning.



07 Certificate

The Professional Master's Degree in Forensic Radiology guarantees students, in addition to the most rigorous and up-to-date education, access to a Professional Master's Degree diploma issued by TECH Technological University.





“

Successfully complete this program and receive your university qualification without having to travel or fill out laborious paperwork”

This program will allow you to obtain your **Professional Master's Degree diploma in Forensic Radiology** endorsed by **TECH Global University**, the world's largest online university.

TECH Global University is an official European University publicly recognized by the Government of Andorra (*official bulletin*). Andorra is part of the European Higher Education Area (EHEA) since 2003. The EHEA is an initiative promoted by the European Union that aims to organize the international training framework and harmonize the higher education systems of the member countries of this space. The project promotes common values, the implementation of collaborative tools and strengthening its quality assurance mechanisms to enhance collaboration and mobility among students, researchers and academics.

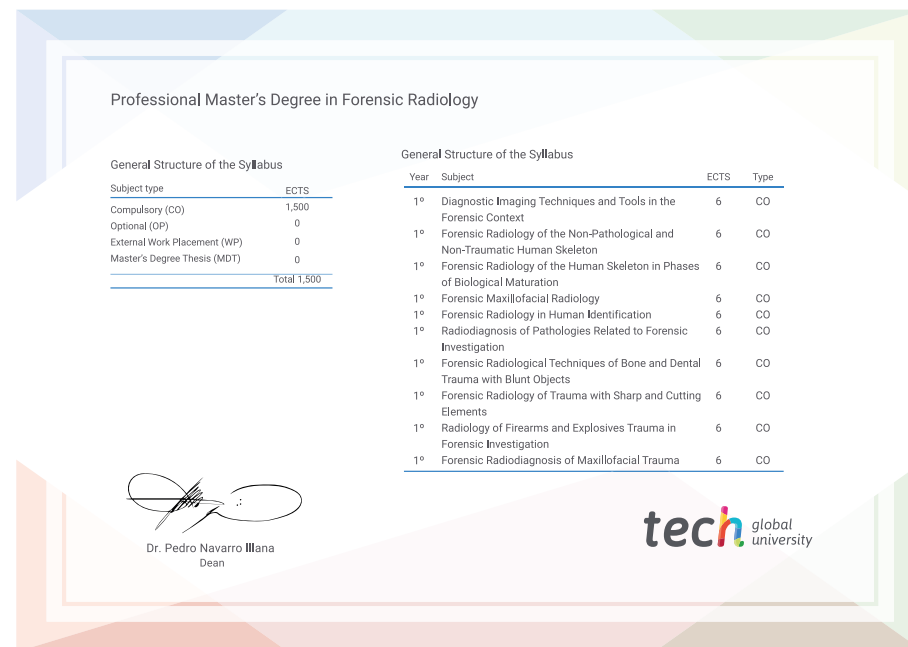
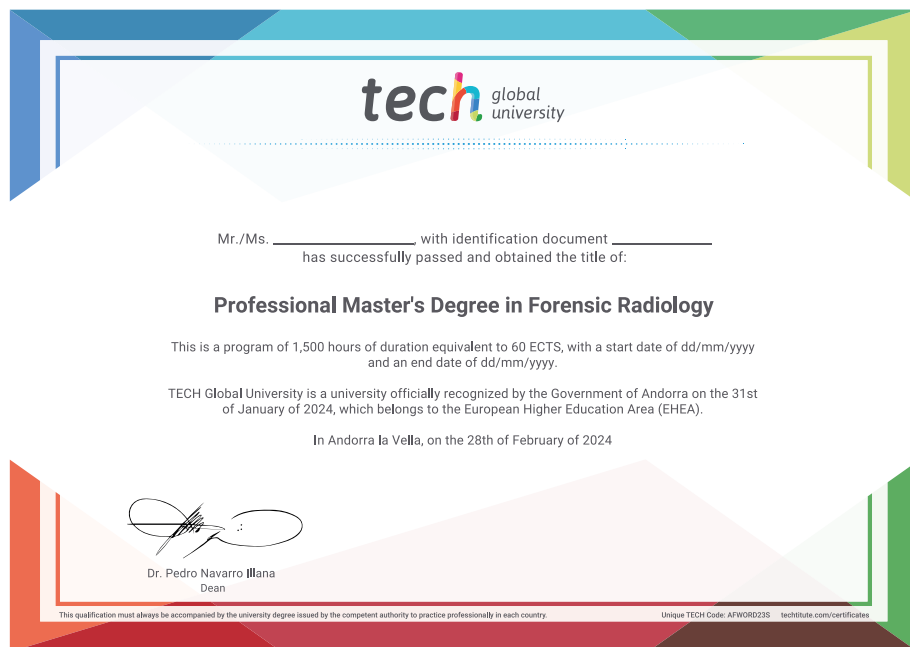This **TECH Global University** title is a European program of continuing education and professional updating that guarantees the acquisition of competencies in its area of knowledge, providing a high curricular value to the student who completes the program.

Title: **Professional Master's Degree in Forensic Radiology**

Mode: **online**

Duration: **12 months**

Accreditation: **60 ECTS**



*Apostille Convention. In the event that the student wishes to have their paper diploma issued with an apostille, TECH Global University will make the necessary arrangements to obtain it, at an additional cost.

future
health confidence people
education information tutors
guarantee accreditation teaching
institutions technology learning
community commitment
personalized service innovation
knowledge present
development language
virtual classroom



**Professional Master's
Degree**
Forensic Radiology

- » Modality: **online**
- » Duration: **12 months**
- » Certificate: **TECH Global University**
- » Credits: **60 ECTS**
- » Schedule: **at your own pace**
- » Exams: **online**

Professional Master's Degree

Forensic Radiology

